

## Heart surgery.

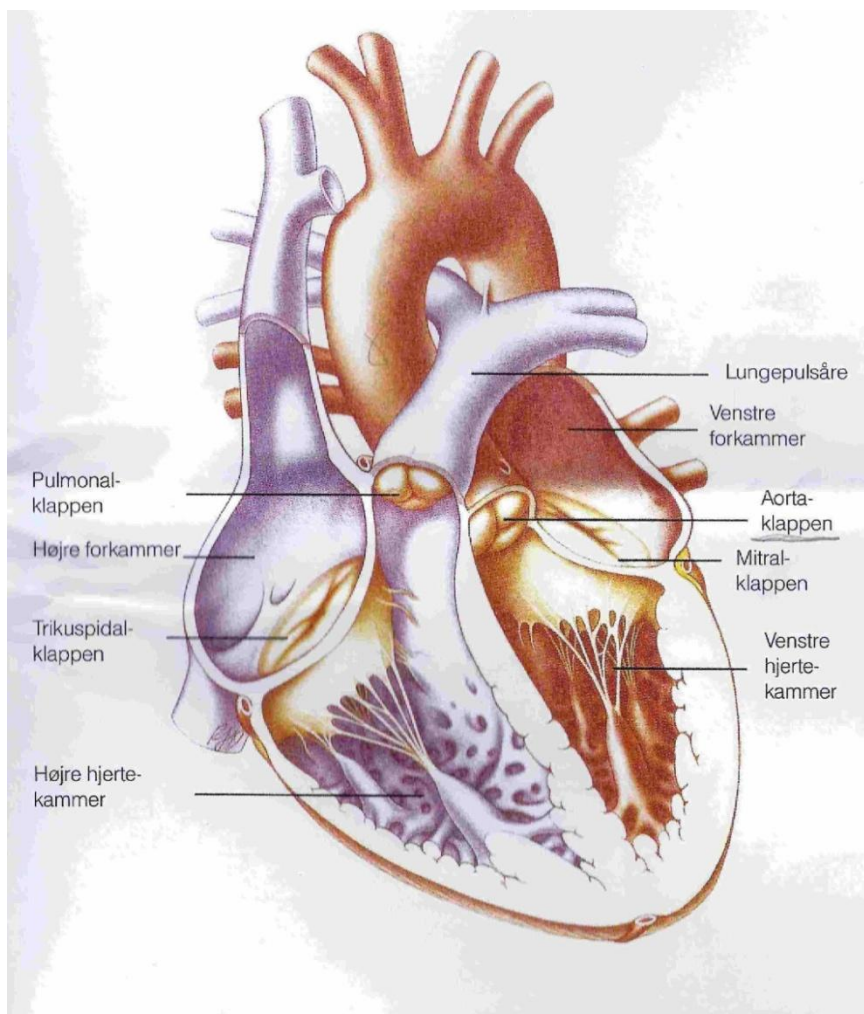
Yes I can start out by telling you that I was born with a heart valve defects (1977) but it was only like 12 -13 years of age it was discovered by I were to school fun run I had a 5 km. but I ran 1 km and went the rest ... it stood at 2 - 3 years in a row So I went home and told my parents that something was wrong when I could only run as little

I came across the mill through with medical and special doctor where you could hear a murmur heart rhythm that my heart valve defects were doing.

Until 2012 I went with it when I had to live after that there were things I could not ... but was also tired of repeatedly that I could not anything due to heart

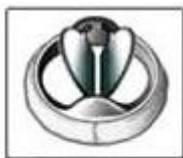During 2012 I have been through several scans and tests ... where the result was assessed at a conference where it was decided that they would offer to get the "sick" heart valve replacement ... when I was told about this, I thought "Yes, finally."

Then came the blow in battle with prospecting and info about the operation etc.



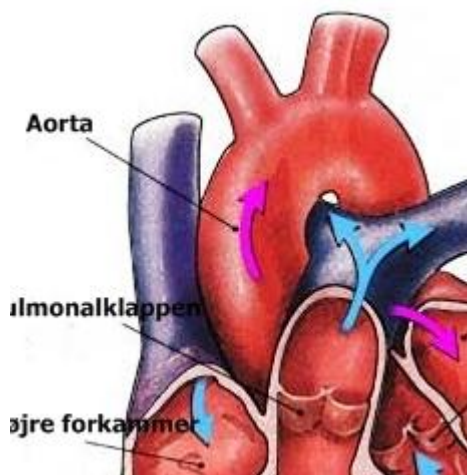
As seen in the picture above is the aortic valve (Aortaklappen)

Where you normally have 3 flaps (I was only born with 2) and therefore closed it does not really



Mekanisk klap

And it's the flap I've been replaced with a mechanical heart valve



And then there was Aortic (Aorta) vein, extended and it may not expand more



so I got a so called prosthetic around. 3 cm long  
to aortic(Aorta) vein does not expand more.

After the operation (on 29/10 - 2012)

I received a visit and soon after came the note or what it calls on facebook from my two brothers:

### Note:

Peter is today had surgery, everything was according to plan, he was very, very tired, but know very well in good mood:)

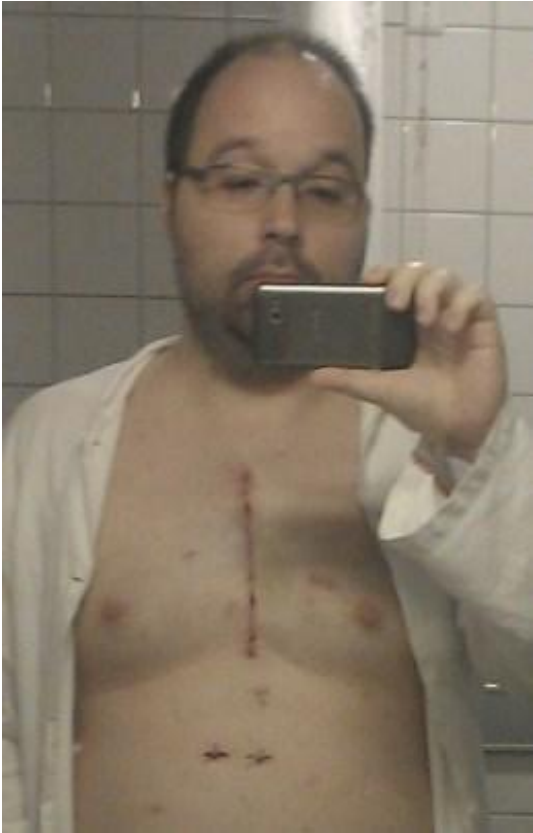My middle brother

### Note:

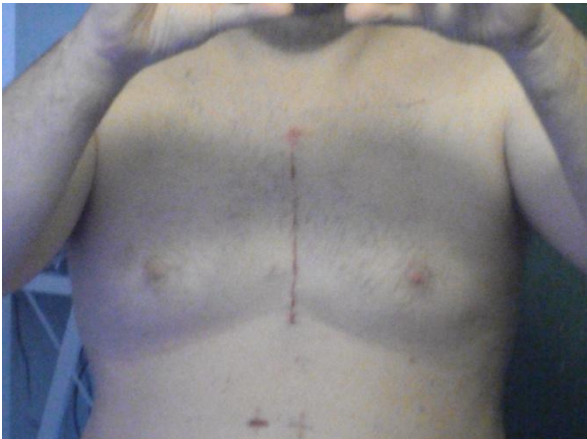What a lovely day ...

Peter has just been through a surgery that has gone perfectly ... So now there soon a new and improved Peter back in version 2.0.

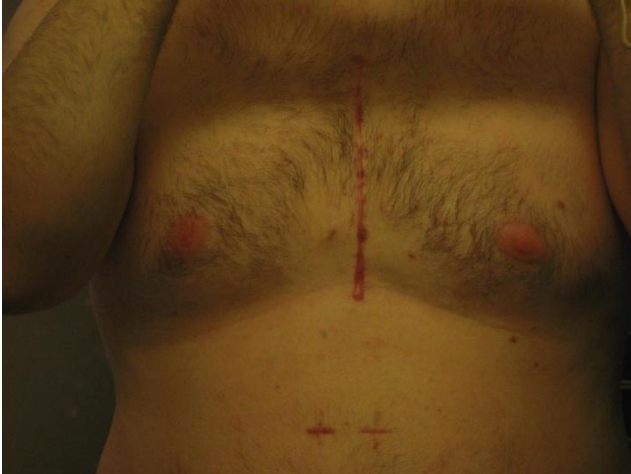My Oldest brother



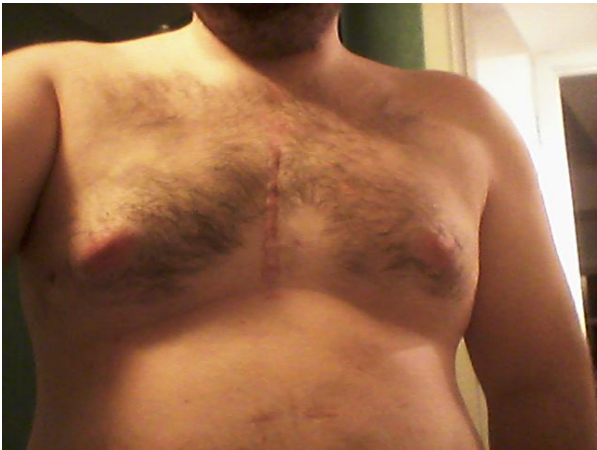This picture was taken about. one week after surgery



This picture was taken about. one month after surgery



This picture was taken about. 2 ½ months after surgery



This picture was taken at 31-12-2013 ... about 1 year after surgery

And it goes well and forward  
Can handle more now than before

Peter Lundgreen Jensen