


Potential causes of ulnar-sided wrist pain



1. Carpometacarpal joint instability
2. Extensor Carpi Ulnaris (ECU) enthesopathy
3. Hook of the hamate fracture or nonunion
4. Chondromalacia of the proximal pole of the hamate
5. Ununited dorsal avulsion of the triquetrum
6. Palmar midcarpal instability
7. Dorsomedial midcarpal instability
8. Capitolunate instability (CLIP syndrome)
9. Lunotriquetral instability (LTq)
10. Fracture of a partial LTq coalition (synchondrosis)
11. Ulnocarpal ligaments rupture or avulsion
12. Pisotriquetral dysfunction
13. Flexor Carpi Ulnaris (FCU) enthesopathy
14. Ulnocarpal meniscoid syndrome
15. Osteoid Osteoma
16. Ulnar Styloid Triquetrum Impaction syndrome (USTI)
17. Triquetral Impingement Ligament Tear syndrome (TILT)
18. Synovitis in the prestyloid recess
19. Triangular Fibrocartilage Complex Injury (TFCC)
20. Ulnocarpal Impaction syndrome
21. Kienbock's disease
22. Dorsal sensory branches of the ulnar nerve injury
23. Guyon's canal nerve entrapment
24. Hypothenar hammer syndrome
25. ECU tenosynovitis
26. ECU sub-sheath injury
27. DRUJ osteoarthritis
28. Triquetro-hamate impaction syndrome
29. DRUJ synovitis

7


Potential causes of ulnar-sided wrist pain



1. Synovitis in the prestyloid recess
2. DRUJ osteoarthritis
3. DRUJ synovitis
4. Ulnocarpal ligaments rupture or avulsion
5. Triangular Fibrocartilage Complex Injury (TFCC)
6. Ulnar Styloid Triquetrum Impaction syndrome (USTI)
7. Ulnocarpal Impaction syndrome
8. Triquetral Impingement Ligament Tear syndrome (TILT)
9. Ulnocarpal meniscoid syndrome
10. Chondromalacia of the proximal pole of the hamate
11. Triquetro-hamate impaction syndrome
12. Palmar midcarpal instability
13. Dorsomedial midcarpal instability
14. Capitolunate instability (CLIP syndrome)
15. Lunotriquetral instability (LTq)
16. Carpometacarpal joint instability
17. Pisotriquetral dysfunction
18. Fracture of a partial LTq coalition (synchondrosis)
19. Osteoid Osteoma
20. Kienbock's disease
21. Extensor Carpi Ulnaris (ECU) enthesopathy
22. Flexor Carpi Ulnaris (FCU) enthesopathy
23. ECU tenosynovitis
24. ECU sub-sheath injury
25. Hypothenar hammer syndrome
26. Dorsal sensory branch of the ulnar nerve injury
27. Guyon's canal nerve entrapment
28. Hook of the hamate fracture or nonunion
29. Ununited dorsal avulsion of the triquetrum

8


Potential causes of ulnar-sided wrist pain



1. Synovitis in the prestyloid recess
2. DRUJ osteoarthritis
3. DRUJ synovitis
4. Ulnocarpal ligaments rupture or avulsion
5. Triangular Fibrocartilage Complex Injury (TFCC)
6. Ulnar Styloid Triquetrum Impaction syndrome (USTI)
7. Ulnocarpal Impaction syndrome
8. Triquetral Impingement Ligament Tear syndrome (TILT)
9. Ulnocarpal meniscoid syndrome
10. Chondromalacia of the proximal pole of the hamate
11. Triquetro-hamate impaction syndrome
12. Palmar midcarpal instability
13. Dorsomedial midcarpal instability
14. Capitolunate instability (CLIP syndrome)
15. Lunotriquetral instability (LTq)
16. Carpometacarpal joint instability
17. Pisotriquetral dysfunction
18. Fracture of a partial LTq coalition (synchondrosis)
19. Osteoid Osteoma
20. Kienbock's disease
21. Extensor Carpi Ulnaris (ECU) enthesopathy
22. Flexor Carpi Ulnaris (FCU) enthesopathy
23. ECU tenosynovitis
24. ECU sub-sheath injury
25. Hypothenar hammer syndrome
26. Dorsal sensory branch of the ulnar nerve injury
27. Guyon's canal nerve entrapment
28. Hook of the hamate fracture or nonunion
29. Ununited dorsal avulsion of the triquetrum

9


Potential causes of ulnar-sided wrist pain



1. Articular problems of the DRUJ
2. Ligament injuries
3. Impaction syndromes
4. Carpal instabilities
5. Other carpal conditions
6. Extracapsular causes of pain

10

INTRACAPSULAR? ... OR EXTRACAPSULAR?




11

- ✓ Introduction
- ✓ Intracapsular causes of pain
- ✓ Extracapsular causes of pain
- ✓ Conclusions


12

Intracapsular pathology causing ulnar-sided wrist pain



1. Articular problems of the DRUJ
2. Ligament injuries
3. Triangular fibrocartilage (TFCC) tears
4. Carpal instabilities
5. Other carpal conditions

13



DRUJ synovitis DRUJ arthropathy

14



DRUJ synovitis DRUJ arthropathy


15



Forearm stiffness secondary to DRUJ & surrounding soft tissue problems may be painful

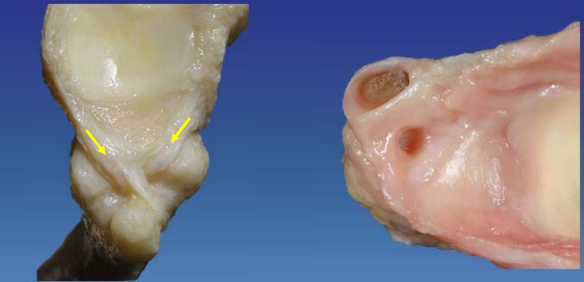
16

Intracapsular pathology causing ulnar-sided wrist pain



1. Articular problems of the DRUJ
2. Ligament injuries
3. Triangular fibrocartilage (TFCC) tears
4. Carpal instabilities
5. Other carpal conditions


17



Distal radioulnar ligaments TFCC surrounding structures

18


Among usual suspects for ulnar-sided pain



... TFCC is almost always found to be guilty

19

1. Clinical exam looks for LAXITY



"Piano-key sign test" "Dimple sign"

20

1. Clinical exam looks for LAXITY




"Distal ulna ballottement test"
(neutral, pronation, supination, radial inclination)

LAXITY & INSTABILITY ARE NOT the same

21

2. Clinical exam looks for PAIN



"TFC grind test" "Press test"

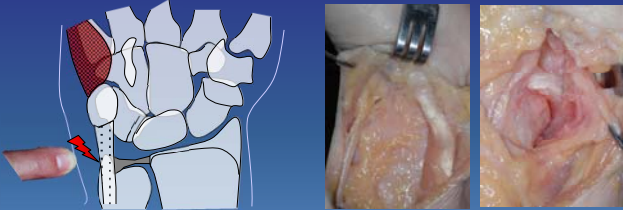
22

2. Clinical exam looks for PAIN



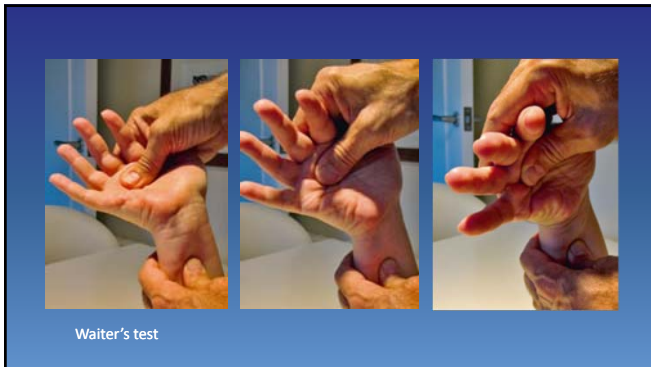
"TFC grind test" "Press test"

23



Fovea test

24



25

Can we trust in clinical exam for ligamentous structures?

Full Length Article

JHS(E)

The reliability of clinical assessment of distal radioulnar joint instability

Greg Thomas Pickering¹, Nicola Francesca Fine², Thomas David Knapper¹ and Grey Edward Bence Giddins¹

Journal of Hand Surgery European Volume 2022, Vol. 47(2) 275-278 © The Author(s) 2022. Reprints and permissions: sagepub.com/journalsPermissions.nav DOI: 10.1177/10991362221104242 sagepub.com/journals.nav

February 22nd 7:30pm GMT

paper one

paper two

hosted by Alex Leach & Matthew Brown

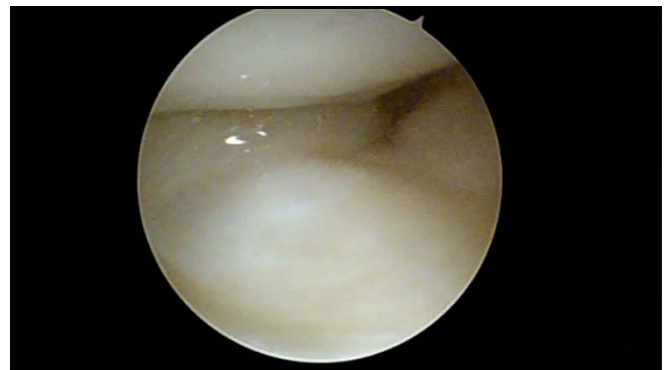with a validated measurement rig. Use of the wrist ballottement test as the primary examination technique yielded a positive predictive value of 81%, a negative predictive value of 55%, a specificity of 94% and a sensitivity of only 24%, for the detection of DRUJ instability. No correlation between background speciality (orthopaedic versus plastic surgery), nor years of clinical experience was found. Clinical assessment of DRUJ instability among experienced clinicians appears unreliable and instability is typically under recognized.

26

Be careful with MR information

Faber K, et al. MR imaging for ulnar wrist pain. J Hand Surg 2010;35A:303-7.

27



28

Intracapsular pathology causing ulnar-sided wrist pain

1. Articular problems of the DRUJ
2. Ligament injuries
3. Impaction syndromes
4. Carpal instabilities
5. Other carpal conditions

29

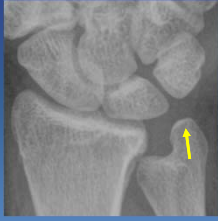1. Ulnocarpal impaction or ulnocarpal abutment sd.

Constitutional

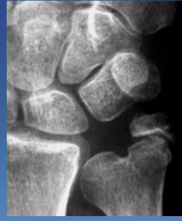
Acquired

30

2. Ulnar styloid-triquetrum impaction syndrome

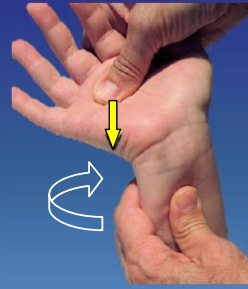

Megastyloid ulnar process



Non-union

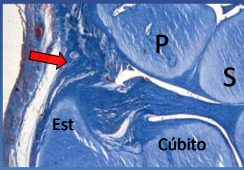
31



"Ulnar styloid triquetrum impaction test"

32

Ulnocarpal meniscoid syndrome



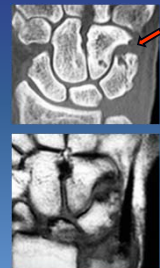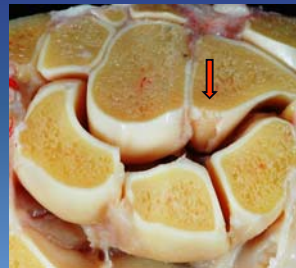
Ulnocarpal meniscoid



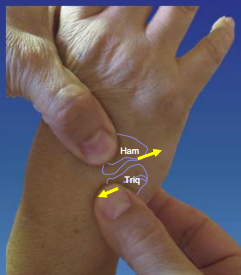"Meniscoid impingement test"

33

3. Luno-hamate & triquetro-hamate impaction sd.



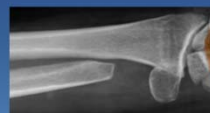34



"Triquetrohamate grinding (or shear) test"

35


4. Radio-ulnar impaction syndrome



Bell et al. Ulnar impingement syndrome. J Bone Joint Surg 1985;67B:126-9

36

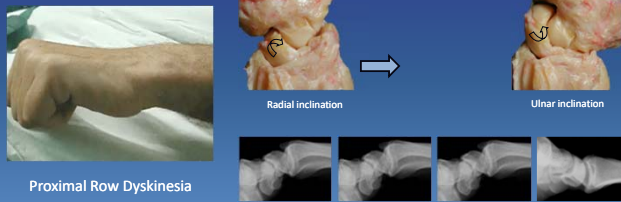
Intracapsular pathology causing ulnar-sided wrist pain



1. Articular problems of the DRUJ
2. Ligament injuries
4. Carpal instabilities
5. Other carpal conditions

37

Palmar Midcarpal Instability (CIND)




Proximal Row Dyskinesia
"Catch-up clunk"

Radial inclination → Ulnar inclination

CLUNK!!!!

38


Luno-triquetral dysfunction



Dynamic Static


39

Intracapsular pathology causing ulnar-sided wrist pain



1. Articular problems of the DRUJ
2. Ligament injuries
4. Carpal instabilities
5. Other carpal conditions

40



Kienböck's disease Osteoid Osteoma Chondrocalcinosis

And some others...

41




Some causes may coexist in the same wrist

42

- ✓ Introduction
- ✓ Intracapsular causes of pain
- ✓ Extracapsular causes of pain
- ✓ Conclusions

43


Around **25%** of wrists with ulnar-sided pain do not derive from an intracapsular but from an extracapsular cause



Looking inside the joint won't solve the problem !!!

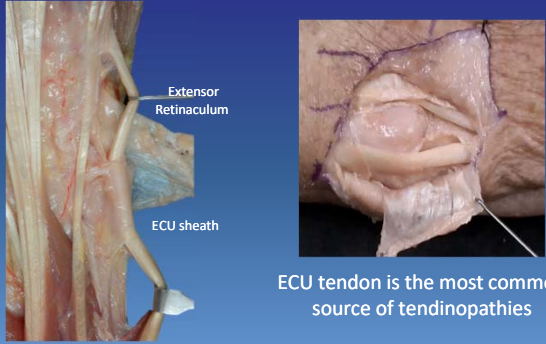
44

Extracapsular pathology causing ulnar-sided wrist pain



- 1. Tendinopathies
- 3. Nerve & vascular

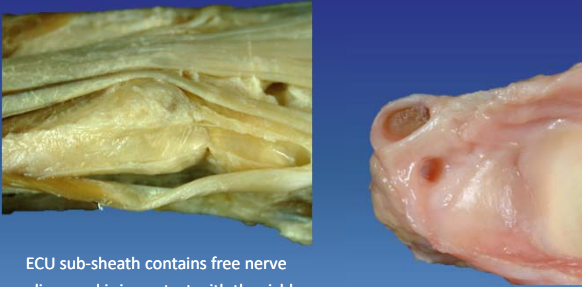
45



Extensor Retinaculum
ECU sheath

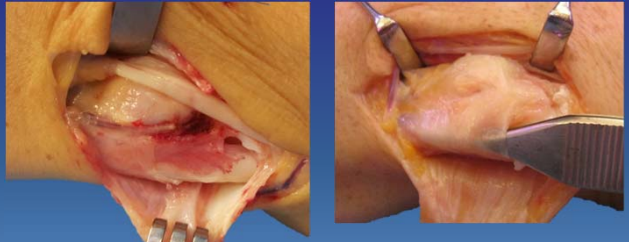
ECU tendon is the most common source of tendinopathies

46



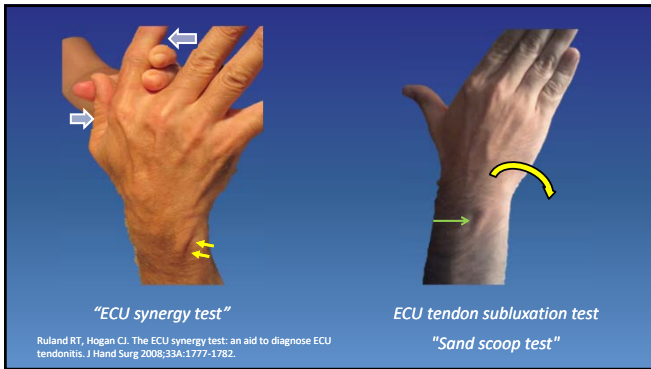
ECU sub-sheath contains free nerve endings and is in contact with the richly innervated ulnocarpal meniscoid

47

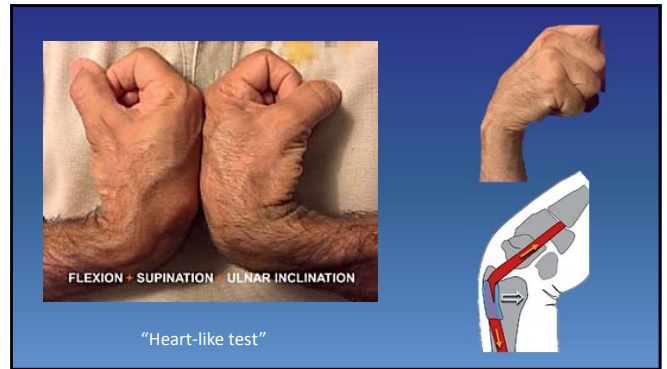


Tenosynovitis Instability

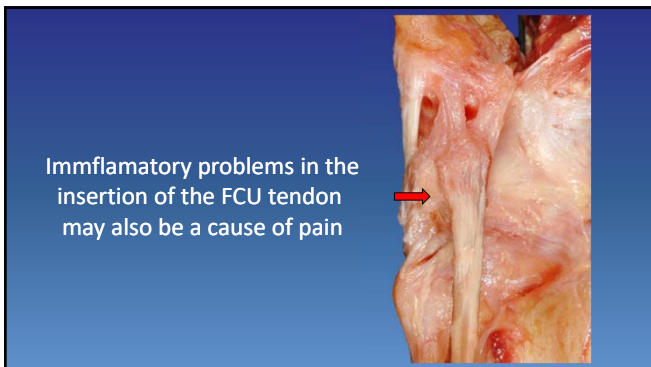
48



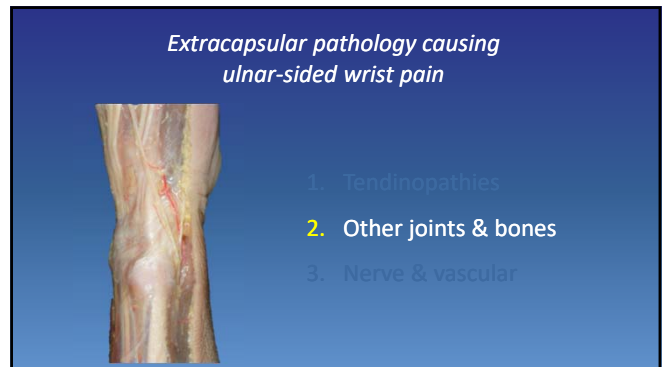49



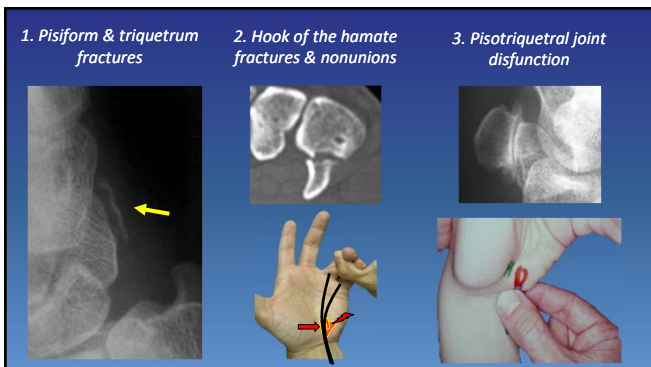
50



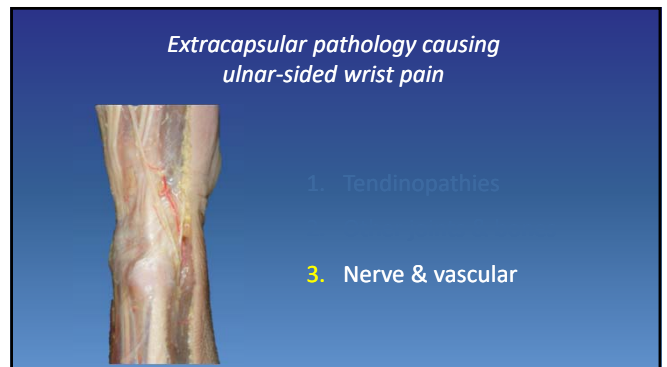
51



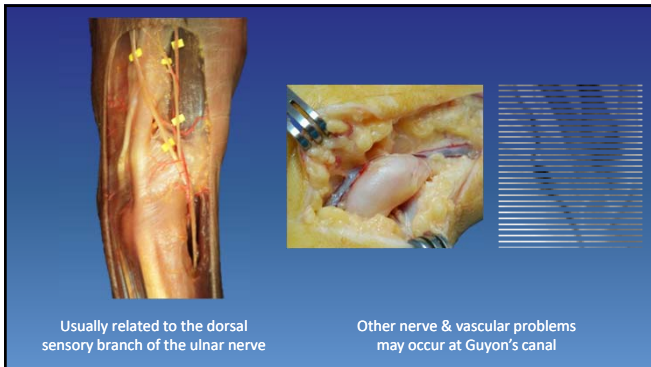
52



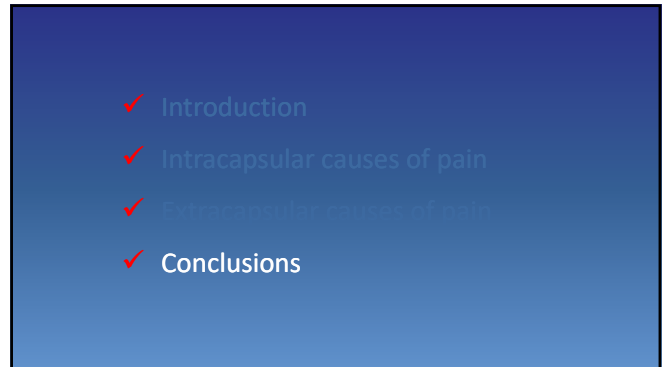
53



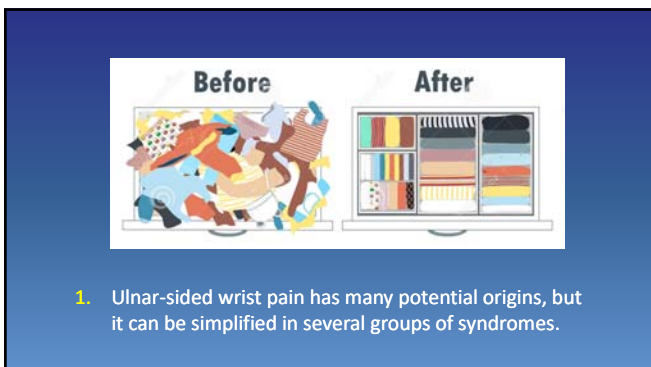
54



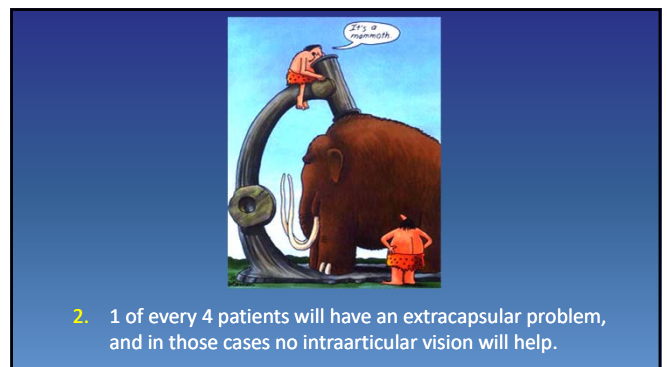55



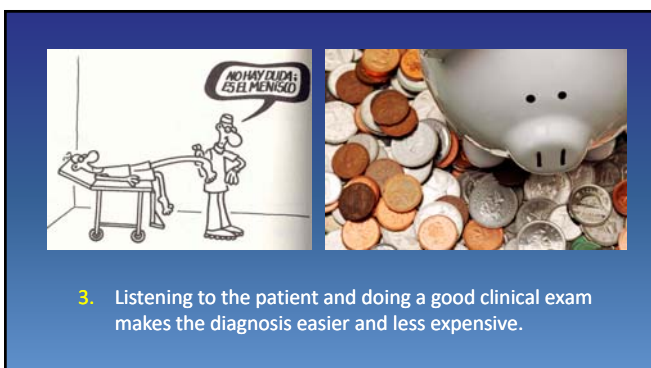
56



57



58




59



60



61



62



63