


RIHM

Instructions for administering the Rotterdam Intrinsic Hand Myometer (RIHM)

A dynamometer to measure the muscle strength of the intrinsic muscles of the hand



Introduction

For many centuries measuring muscle strength has been an area of interest for those who have been studying and are responsible for diagnosing many diseases that are accompanied by loss of strength. Numerous neurological diseases are accompanied by atrophy of the intrinsic muscles of the hand.

Assessing the strength of the intrinsic muscles is of great importance in clinical neurology in the evaluation of mono- and poly-neuropathies. Similarly in spinal cord injury because the intrinsic muscles are innervated by the most caudal cord segments.(Jacquemin et al. 2004) It has been noted that there is a need for an accurate device for these muscles.(van der Ploeg 1992)

One of the first to develop a dynamometer for the intrinsic muscle strength was Mannerfelt, who later manufactured a new device called the *Intrins-o-meter*.(Mannerfelt 1966) In 1997 he reported a study in 48 patients with ulnar nerve compression.(Mannerfelt 1997) Several others have developed instruments mainly to assess the abduction of the thumb.(Trumble et al. 1995; Boatright et al. 1997; Liu et al. 2000) Some needed a specially constructed jig, e.g. to measure wrist, finger (metacarpo-phalangeal joints) and thumb extension strength.(Richards et al. 1993)

The Rotterdam Intrinsic Hand Myometer (RIHM) is a hand-held dynamometer with the advantage of an easy-to-hold, ergonomic handgrip and a different method of giving resistance i.e. by means of pulling, in which the angle of the applied strength is easy to control. Several articles have been published.(Schreuders et al. 2004a; Schreuders et al. 2004c; Schreuders et al. 2004b; Schreuders et al. 2006; Selles et al. 2006)

The RIHM was mentioned in a review of BMC Musculoskelet Disord. 2007 Nov 20;8:114(Geere et al. 2007) which concluded: *Although used most frequently and known to be reliable, power and key pinch dynamometry are not the most valid or responsive tools for assessing motor outcome up to 12 weeks following surgery for CTS. Tip pinch dynamometry more specifically targets the thenar musculature and appears to be more responsive. Manual muscle testing, which in theory is most specific to the thenar musculature, may be more sensitive if assessed using a hand held dynamometer – the Rotterdam Intrinsic Handheld Myometer. However further research is needed to evaluate its reliability and responsiveness and establish the most efficient and psychometrically robust method of evaluating motor function following surgery for CTS.*

With the RIHM dynamometer it is possible to measure for the:

Median nerve:	Abduction of the thumb (primarily caused by Abductor Pollicis Brevis) Opposition of the thumb (primarily caused by Opponens Pollicis)
Ulnar nerve:	Abduction index finger (solitary caused by first dorsal interosseous muscle) Abduction little finger (hypothenar muscles) Adduction little finger (solitary third palmar interosseous)
Combined ulnar and median nerves	Intrinsic plus position (combination of interosseous and lumbrical muscles) Flexion of the MCP joint of the thumb (mostly FPB)

Reliability has been established in patients with peripheral nerve injuries. (Schreuders et al. 2004c; Schreuders et al. 2004b) and is comparable to grip and pinch strength measurements. Differences between 2 measurements greater than 6.3 N were interpreted as a real (95%) change in assessing the strength of the abduction of the little and index finger; for the median innervated muscles of the thumb this value was 16 N.

Testing protocol

The examiner and patient are seated at opposite sides of a table. The patient is shown how to hold the finger or thumb and instructed that he/she should try to keep the finger or thumb in that position with maximum strength.

The strength on the finger or thumb is slowly increased while the examiner verbally encourages the patient to hold the finger or thumb in place. After one second the tester pulls to 'break' the movement and relaxes. This is the so-called break test (Ketchum et al. 1978) and repeated three times.

The place at which the sling is applied is similar to the anatomical reference points of the manual muscle testing as described by Brandsma et al. (Brandsma et al. 1995; Brandsma and Schreuders 2001) Usually an anatomical reference point like the joint crease of the PIP joint is chosen. It is important to control the perpendicular application and especially to control the point of application of the sling as accurate as possible.

Registration:



Similar to grip strength measurements, all tests are repeated three times and the mean of three measurements is registered.

See the suggested form (page 8)



Ulnar nerve innervated muscles:

Ulnar abduction of the little finger.

The patient's hand is supinated while the second, third and fourth fingers are held by the examiner's hand. The patient's little finger is placed in maximum abducted position with the MP joint in slight flexion. The patient is told to keep the finger in that position while the sling of the dynamometer is applied at the PIP joint of the little finger. The pull is always perpendicular to the axis of the little finger; parallel to the palm of the hand.



Radial abduction of the index finger (mainly the first dorsal interosseous muscle). The patient's hand is in pronation and the third, fourth and fifth fingers are held by the examiner. The point at which the sling is applied is at the radial side of the PIP joint of the index finger. The pull is always perpendicular to the finger; parallel to the palm of the hand.



Intrinsic action (intrinsic muscles of the fingers combined)

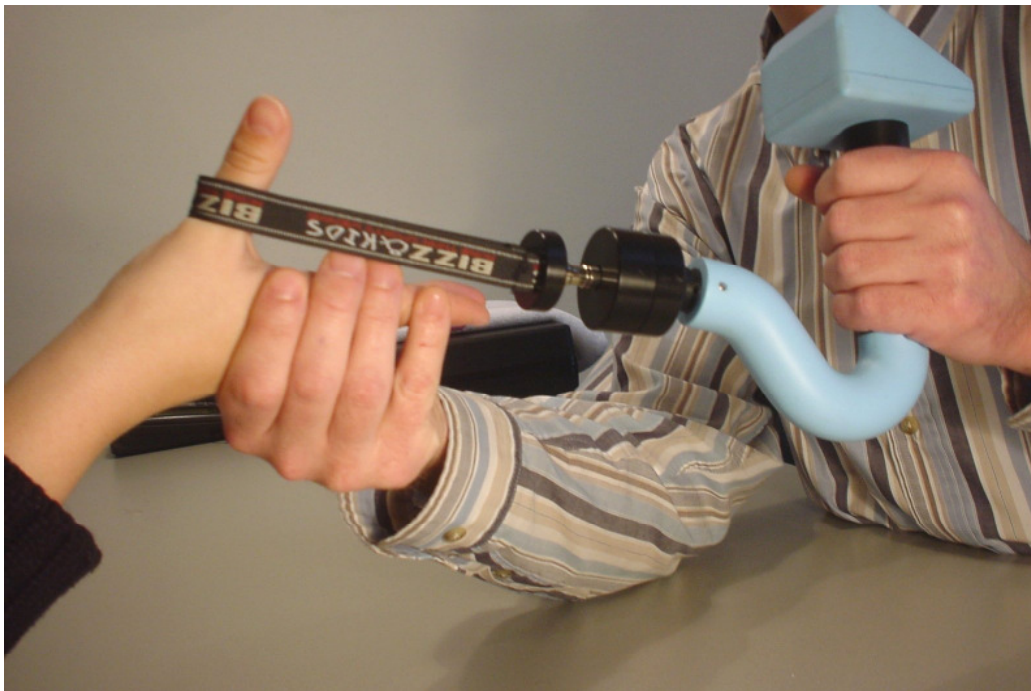The hand of the patient lies on the table with the ulnar side of the hand, while the patient is holding the hand in intrinsic plus position; MCP flexed and IP extended. The sling is applied at the PIP joint of the finger. The patient is told not to adduct the fingers.

The pull is perpendicular to the finger until the PIP joint flexes.




Median nerve innervated muscles:

Palmar abduction of the thumb. (or anteposition(IFSSH 2001)) The lower arm is in supination with the elbow resting on the table with the wrist manually supported by the examiner in dorsiflexion. The sling is applied at the MP joint level of the thumb. The patient is asked to move the thumb away from the palm of the hand. The pull is in one line with the flexion-extension axis of the MP joint of the thumb.



Opposition of the thumb. The lower arm is supinated and all fingers of the hand are fixed flat on the table by the examiner. The pull is at the MP joint in a horizontal plane in line with the palm of the hand. The patient is instructed not to flex the interphalangeal joint of the thumb.



Flexion MCP thumb (FPB)

The lower arm is supinated and all fingers of the hand are fixed flat on the table by the examiner. The sling is applied at the proximal phalanx of the thumb perpendicular to the axis of flexion-extension of the MCP joint of the thumb. The patient is asked to maintain the thumb in the flexed position of MCP flexion and instructed not to flex the interphalangeal joint of the thumb.

Score form - RIHM measurements

Name: _____

Date of birth: _____

Nerve: ulnar/median/radial

Injured hand: Right/ Left

dominant hand: Right/ Left

Measurement date: _____

tester: _____

		RIGHT				LEFT			
Nerve	movement	1	2	3	Mean	1	2	3	Mean
Ulnar	Abduction index finger								
	Abduction little finger								
	Adduction little finger								
Median	Abduction thumb								
	Opposition thumb								
Combined	Flexion MCP								
	Intrinsic plus pos. index								
	Intrinsic plus pos. middle								
	Intrinsic plus pos. ring								
	Intrinsic plus pos. little								

Measurement date: _____

tester: _____

		RIGHT				LEFT			
Nerve	movement	1	2	3	Mean	1	2	3	Mean
Ulnar	Abduction index finger								
	Abduction little finger								
	Adduction little finger								
Median	Abduction thumb								
	Opposition thumb								
Combined	Flexion MCP								
	Intrinsic plus pos. index								
	Intrinsic plus pos. middle								
	Intrinsic plus pos. ring								

References

- Boatright JR, Kiebzak GM, O'Neil DM, Peindl RD. Measurement of thumb abduction strength: normative data and a comparison with grip and pinch strength. *J Hand Surg [Am]* 1997;22(5):843-848.
- Brandsma JW, Schreuders TA. Sensible manual muscle strength testing to evaluate and monitor strength of the intrinsic muscles of the hand: a commentary. *J Hand Ther* 2001;14(4):273-278.
- Brandsma JW, Schreuders TA, Birke JA, Piefer A, Oostendorp R. Manual muscle strength testing: intraobserver and interobserver reliabilities for the intrinsic muscles of the hand. *J Hand Ther* 1995;8(3):185-190.
- Geere J, Chester R, Kale S, Jerosch-Herold C. Power grip, pinch grip, manual muscle testing or thenar atrophy - which should be assessed as a motor outcome after carpal tunnel decompression? A systematic review. *BMC Musculoskelet Disord* 2007;8:114.
- IFSSH. Terminology for Hand Surgery.
- Jacquemin GL, Burns SP, Little JW. Measuring hand intrinsic muscle strength: normal values and interrater reliability. *J Spinal Cord Med* 2004;27(5):460-467.
- Ketchum LD, Thompson D, Pocock G, Wallingford D. A clinical study of forces generated by the intrinsic muscles of the index finger and the extrinsic flexor and extensor muscles of the hand. *J Hand Surg [Am]* 1978;3(6):571-578.
- Liu F, Carlson L, Watson HK. Quantitative abductor pollicis brevis strength testing: reliability and normative values. *J Hand Surg [Am]* 2000;25(4):752-759.
- Mannerfelt L. Studies on the hand in ulnar nerve paralysis. A clinical-experimental investigation in normal and anomalous innervation. *Acta Orthop Scand* 1966(87):61-86.
- Mannerfelt LG. Studies on ulnar nerve compression neuropathies with a new computerised instrument--the intrinsic-o-meter. *Scand J Plast Reconstr Surg Hand Surg* 1997;31(3):251-260.
- Richards RR, Gordon R, Beaton D. Measurement of wrist, metacarpophalangeal joint, and thumb extension strength in a normal population. *J Hand Surg [Am]* 1993;18(2):253-261.
- Schreuders TA, Roebroek ME, Jaquet JB, Hovius SE, Stam HJ. Measuring the strength of the intrinsic muscles of the hand in patients with ulnar and median nerve injuries: reliability of the Rotterdam Intrinsic Hand Myometer (RIHM). *J Hand Surg [Am]* 2004a;29(2):318-324.
- Schreuders TA, Selles RW, Roebroek ME, Stam HJ. Strength measurements of the intrinsic hand muscles: a review of the development and evaluation of the Rotterdam intrinsic hand myometer. *J Hand Ther* 2006;19(4):393-401; quiz 402.
- Schreuders TAR, Roebroek ME, Jaquet J-B, Hovius SER, Stam HJ. Long-term outcome of muscle strength in patients with ulnar and median nerve injury: Comparing manual muscle strength testing, grip and pinch strength dynamometers and a new intrinsic muscle strength dynamometer. *J Rehabil Med* 2004b;36:273-278.
- Schreuders TAR, Roebroek ME, Jaquet J-B, Hovius SER, Stam HJ. Measuring the Strength of the Intrinsic Muscles of the Hand in Patients with Ulnar and Median Nerve Injury; Reliability of the Rotterdam Intrinsic Hand Myometer (RIHM). *J Hand Surg (Am)* 2004c;29A(2):318-324.
- Selles RW, van Ginneken BT, Schreuders TA, Janssen WG, Stam HJ. Dynamometry of intrinsic hand muscles in patients with Charcot-Marie-Tooth disease. *Neurology* 2006;67(11):2022-2027.
- Trumble TE, Kahn U, Vanderhooft E, Bach AW. A technique to quantitate motor recovery following nerve grafting. *J Hand Surg [Am]* 1995;20(3):367-372.
- van der Ploeg RJO. Hand-held dynamometry. (Thesis)

For more information contact:

Ton A.R. Schreuders (PT, PhD)
Department of Rehabilitation Medicine
PO BOX 2040
3000 CA Rotterdam the Netherlands
Tel. +31 10 703 8160
Fax +31 10 703 3843

E-mail a.schreuders@erasmusmc.nl

Websites with information

www.erasmusmc.nl/47580/51019/hand/RIHM

Manuals, forms and instructions, normal values, articles,
pictures and video instructions can be found here:

www.handweb.eu/RIHM/