

Microglial phenotypes differ according to gene mutation in familial frontotemporal dementia

Ione Woollacott¹, Christina Murray^{2,3}, Bridget Benson², Yau Lim⁴, Catherine Strand², Robert Courtney², Jason Warren¹, Jonathan Rohrer¹ and Tammarny Lashley^{2,5}

¹Dementia Research Centre, Department of Neurodegenerative Diseases, UCL Queen Square Institute of Neurology, London, UK, ²Queen Square Brain Bank for Neurological Disorders, Department of Movement Disorders, UCL Queen Square Institute of Neurology, London, UK, ³UK Dementia Research Institute, UCL, London, UK, ⁴King's College London, Institute of Psychiatry, Department of Psychology & Neuroscience, London, UK, ⁵Department of Neurodegenerative Diseases, UCL Queen Square Institute of Neurology, London, UK

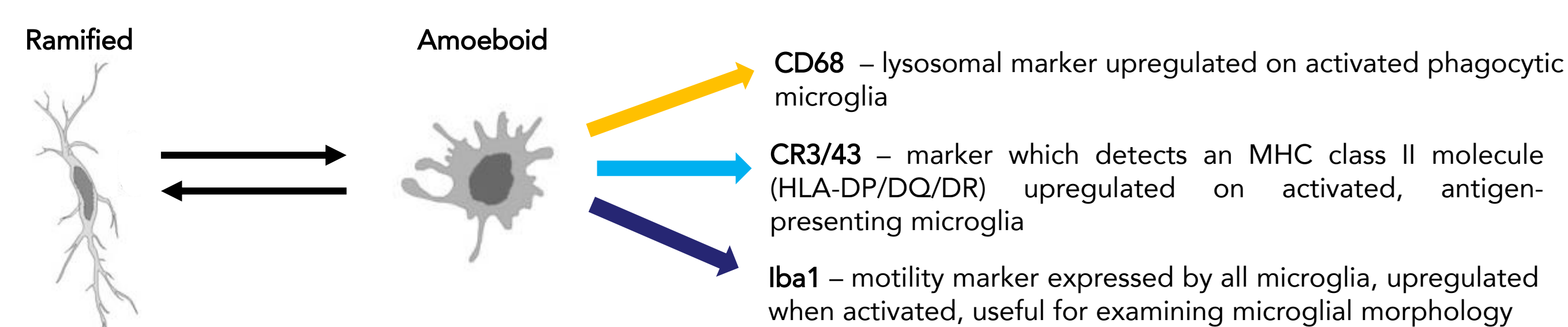


Introduction

Multiple lines of evidence now link chronic microglial dysfunction to frontotemporal dementia (FTD). Mouse models of mutations in progranulin (*GRN*) are associated with excessive microglial activation and altered phagocytosis, but this may also occur due to mutations in chromosome 9 open reading frame 72 (*C9orf72*) or microtubule associated protein tau (*MAPT*). Understanding more about microglial dysfunction in FTD may elucidate how mutations lead to regional disease patterns and help to identify novel treatment targets.

Microglia exist within the brain as a spectrum of phenotypes and activation states. Markers expressed by microglia can help us to determine the presence and activation state of various microglial phenotypes within a brain region (Figure 1). This allows an appreciation of microglial function in that region.

Figure 1. Microglial activation states and three different microglial markers. Microglia can change their morphology between ramified (surveillance/sensing) and amoeboid (activated/aggressive) states, and express different markers according to their predominant phenotype and role



A spectrum of microglial phenotypes has not previously been explored in human brain tissue from individuals with frontotemporal lobar degeneration (FTLD) due to mutations in *GRN*, *C9orf72* and *MAPT*. We examined the expression of three microglial markers (CD68, CR3/43 and Iba1) in a cohort of individuals with familial FTLD, and healthy controls, to explore the burden and activation state of microglia in both the cortical grey and subcortical white matter of clinically relevant brain regions.

Methods

Cohort (Table 1): 15 patients with familial FTLD, including 10 with FTLD-TDP type A (*GRN*, n=5 and *C9orf72*, n=5) and 5 with FTLD-tau (all with *MAPT* 10+16 mutations), and 5 healthy age-matched controls. Cases were obtained from the Queen Square Brain Bank for Neurological Disorders, UCL Queen Square Institute of Neurology, and the MRC London Neurodegenerative Diseases Brain Bank, Institute of Psychiatry, King's College London, UK. All patients with FTLD had undergone detailed clinical, neuropsychological and imaging assessment and genetic analysis. Healthy controls had no neurological disease and no significant neuropathological abnormalities. All cases had undergone detailed routine post-mortem histological examination.

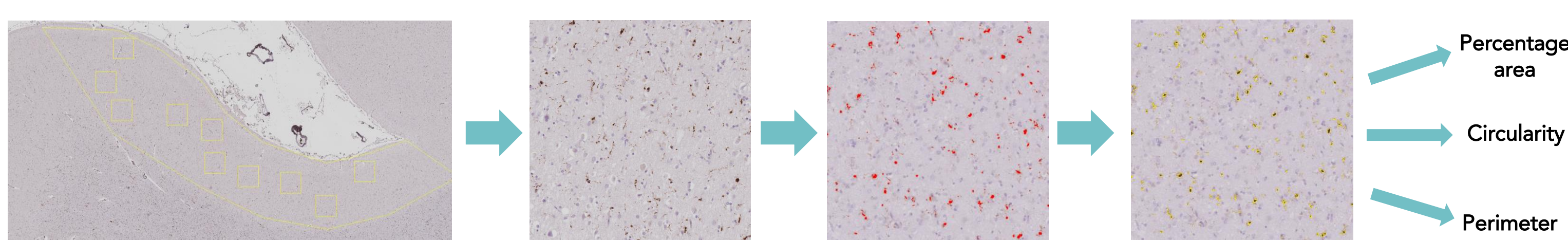
Table 1. Demographics of cases in cohort

Group (N)	Clinical diagnosis	Gender	Mean (range) age at symptom onset in years	Mean (range) age at death in years	Mean (range) disease duration in years	Mean post-mortem delay in hours
Control (5)	Healthy control	Male = 1 Female = 4	n/a	67.4 (38.0-80.0)	n/a	45.7
<i>GRN</i> (5) (all FTLD-TDP A)	bvFTD = 4 nvPPA = 1	Male = 2 Female = 3	58 (50-67)	64.6 (55.3 - 74.2)	6.6 (5.3 - 8.4)	83.1
<i>C9orf72</i> (5) (all FTLD-TDP A)	FTD-MND = 3 nvPPA = 2	Male = 1 Female = 4	60.8 (55-68)	68.6 (62.7 - 75.1)	7.8 (5.7 - 10.3)	57.3
<i>MAPT</i> 10+16 (5) (all FTLD-MAPT)	bvFTD = 5	Male = 2 Female = 3	48 (37-58)	69.6 (52.4 - 68.4)	11.6 (8.1 - 16.4)	45.9

Immunohistochemistry: Coronal brain tissue slices were cut at 5mm thickness from fixed right hemispheres of each case and processed into paraffin-embedded blocks. Sections were cut at 8µm thickness from frontal and temporal cortex blocks and placed onto slides. These underwent standard immunohistochemistry using primary antibodies to detect CD68 (Dako, 1:100), CR3/43 (Dako, 1:150) and Iba1 (Wako Chemicals, 1:1000) and stained sections were mounted onto slides for analysis.

Analysis: Slides were digitally scanned at 40x and images loaded into Leica Aperio Imagescope software. Four clinically relevant subregions were identified for analysis: frontal grey (FG), frontal white (FW), temporal grey (TG) and temporal white (TW) matter. An area within each of these subregions was selected using Imagescope and a macro using Image J and Python software used to quantify the average percentage area containing microglia (burden) and the circularity and perimeter (activation state) of microglia for each of the three markers in each subregion (FG, FW, TG, TW) (Figure 2). Abnormal morphology of stained microglia was also qualitatively assessed (e.g. evidence of beading or fragmentation indicating microglial dystrophy).

Figure 2. Method for analysis of microglial burden and activation state for each marker in each brain subregion



A - An area of interest is manually selected within a brain subregion (e.g. within frontal grey matter) and ten squares are randomly generated for analysis

B - In each square, stained microglia are identified through colour saturation thresholding (which detects brown cellular chromogen)

C - Only microglia above a pre-set staining threshold are selected and chosen for analysis (selected microglia in red)

D - Only microglia above a pre-set diameter (circumscribed in yellow) are selected, to exclude analysis of partial microglial processes

E - A macro in ImageJ is used to calculate the percentage area of a square covered in stained microglia (burden of microglia). Each microglial cell's shape is also individually measured in each square using the hull and circle function in Image J to give a measure of circularity between 0 and 1, where 0 = imperfect/very ramified shape and 1 = perfect circle (activated/very amoeboid shape). The average perimeter of microglial cells is also calculated in each square (lower perimeter = more activated/amoeboid). When averaged across the ten squares, higher circularity and/or lower perimeter values indicate an increased activation state of microglia detected in that subregion.

Statistics: Parameters were averaged across the ten sample squares within the subregion of interest (FG, FW, TG or TW) and then averaged across all cases within each group to produce a group result for microglial percentage area, circularity and perimeter in that subregion. Kruskal Wallis analyses with Dunn's post hoc tests were used to compare microglial percentage area, circularity and perimeter within the same subregion between all groups (controls, *GRN*, *C9orf72* and *MAPT*). Wilcoxon matched pairs signed rank test was used to compare parameters between grey and white matter subregions within each lobe (FG vs. FW, and TG vs. TW) for each group. Significance was determined as P<0.05.

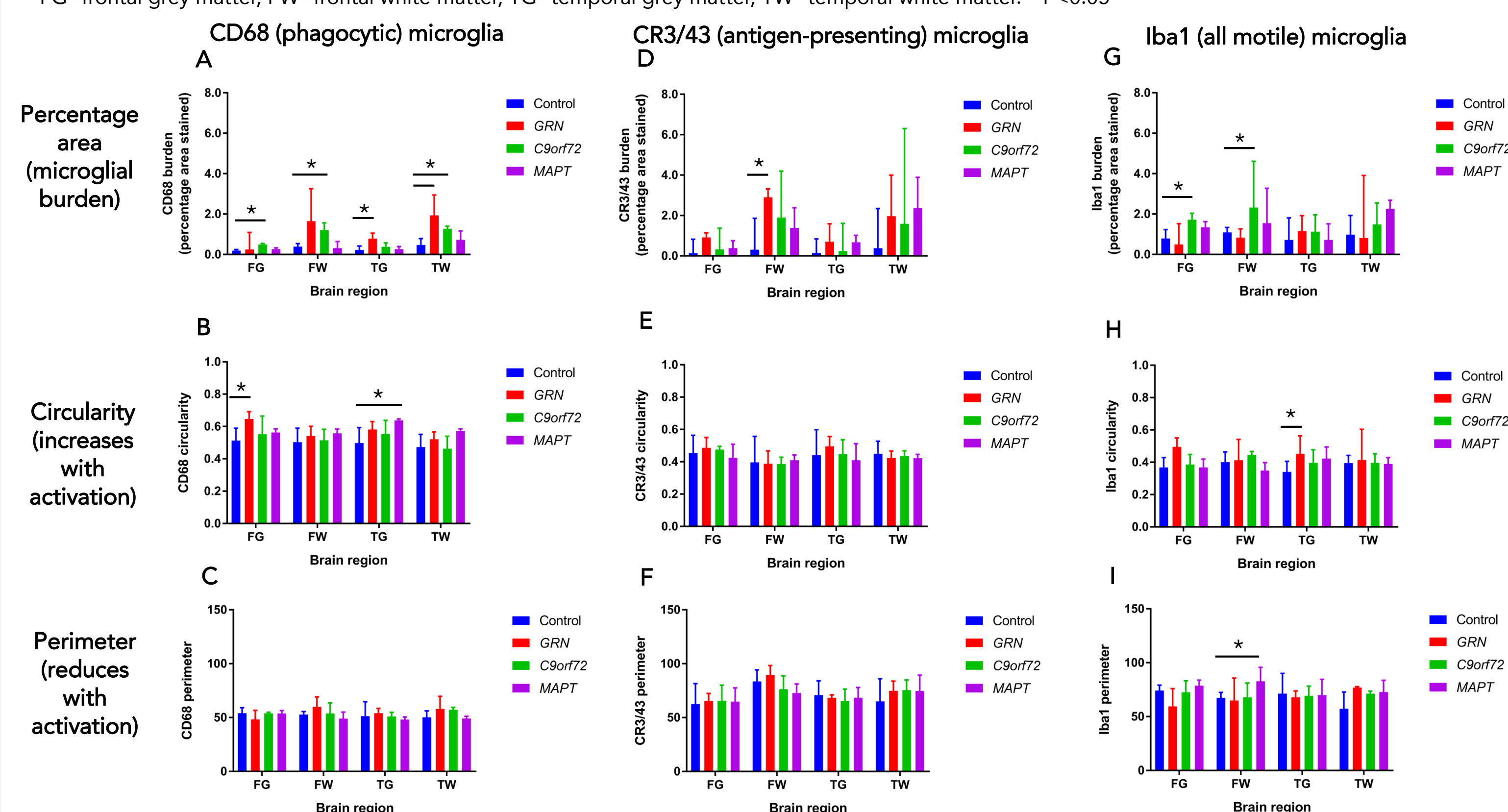
Results

Microglial burden and activation state differ between familial FTLD and controls in the frontal and temporal lobes. This varies by gene, brain subregion and microglial phenotype (Figures 3 and 4):

- GRN group – FRONTAL & TEMPORAL pattern of microgliosis**
 - FW: higher burden of CD68 positive microglia than controls (Fig. 3D, 4D), but these were not more activated (Fig. 3E, 3F). Very dystrophic Iba1 positive microglia (Fig. 4F).
 - TW: higher burden of CD68 positive microglia than controls (Fig. 3A), but not more activated (Fig. 3B, 3C). TG: higher burden of CD68 positive microglia than controls (Fig. 3A). More activated CD68 positive microglia in FG (Fig. 3B) and Iba1 positive microglia in TG (Fig. 3H).
- C9orf72 group – FRONTAL (& temporal) pattern of microgliosis**
 - FG and FW: higher burden of CD68 positive microglia (Fig. 3A, 4G and 4H) and Iba1 positive microglia (Fig. 3G, 4K and 4L) than controls but these were not more activated (Fig. 3B, 3H, 3I). TW: higher burden of CD68 positive microglia than controls (Fig. 3A), again not more activated.

- MAPT group – TEMPORAL pattern of microgliosis**
 - TG: more activated CD68 positive microglia than controls (Fig. 3B) but similar burden (Fig. 3A, 4M)
 - FW: less activated Iba1 positive microglia than controls (Fig. 3I)

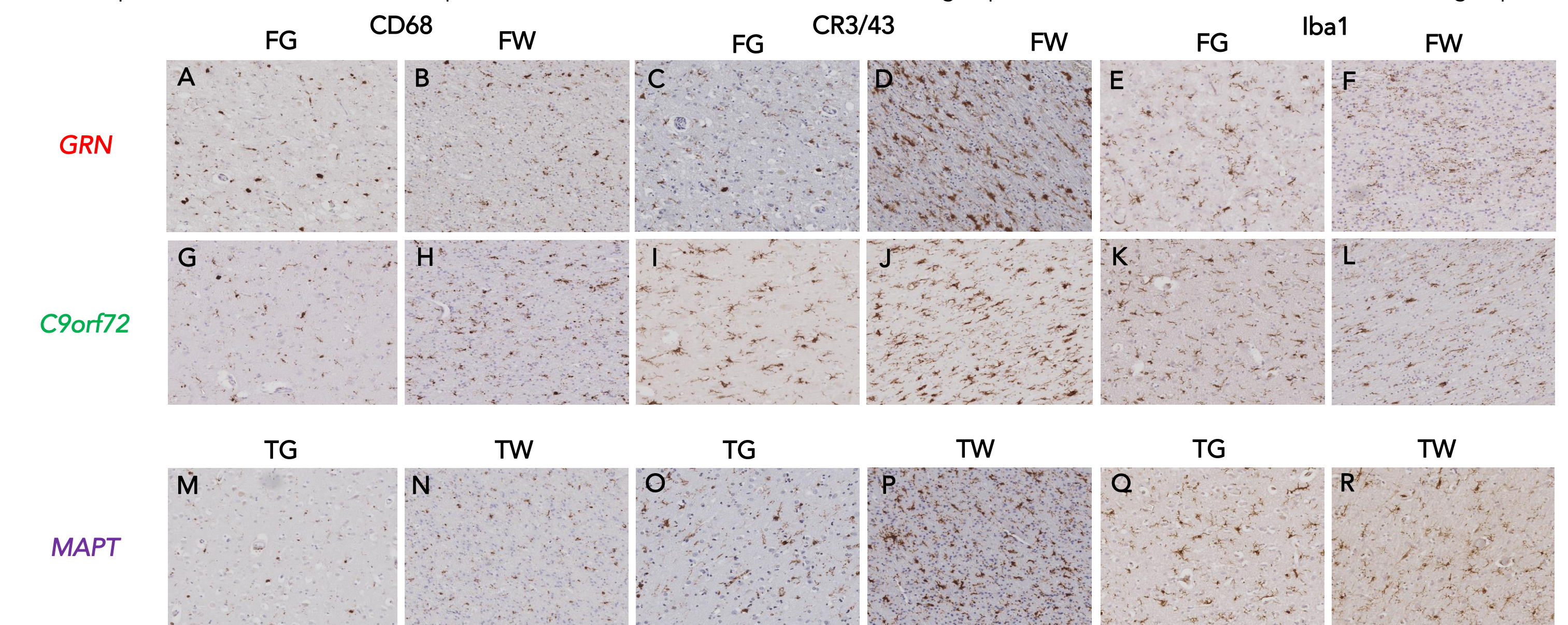
Figure 3. Percentage area, circularity and perimeter for each microglial phenotype compared between familial FTLD groups and controls in each brain region. FG=frontal grey matter, FW=frontal white matter, TG=temporal grey matter, TW=temporal white matter. * P<0.05



Microglial burden and activation states differ between grey and white matter within lobes, according to the underlying gene mutation and lobe examined (Figure 4):

- GRN and C9orf72 groups - frontal and temporal white matter microgliosis and prominent dystrophy**
 - FW and TW contain a higher burden of CD68 positive (phagocytic) and CR3/43 positive (antigen-presenting) microglia than FG and TG (see Fig. 4A-4D for *GRN* and Fig. 4G-4J for *C9orf72*). However, CD68 microglia are less activated in white matter than in grey matter.
 - FW contains severely dystrophic Iba1 positive microglia in the *GRN* group (Fig. 4F) but only mildly dystrophic Iba1 positive microglia in the *C9orf72* group (Fig. 4L).
- MAPT group – temporal white matter microgliosis, but more activated in grey matter**
 - TW contains a higher burden of CD68 positive (phagocytic) and CR3/43 positive (antigen-presenting) microglia than TG (Fig. 4N vs. 4M and Fig. 4P vs. 4O), but CD68 positive microglia are more activated in TG than TW (Fig. 4M vs. 4N).

Figure 4. Microglial burden and activation state (ramified or amoeboid morphology) in grey versus white matter within frontal and temporal lobes for each microglial marker. FG=frontal grey matter, FW=frontal white matter, TG=temporal grey matter, TW=temporal white matter. Significant differences between panels are described above. Temporal lobe slides not shown for *GRN* and *C9orf72* groups and frontal lobe slides not shown for *MAPT* group.



Conclusions

- There are differences in the burden and activation state of different microglial phenotypes (phagocytic, antigen-presenting and motile microglia) within the frontal and temporal lobes of patients with familial FTLD compared with healthy controls.
- Microglial patterns in familial FTLD seem to depend on the underlying mutation. *GRN* carriers have a high burden of less activated microglia in frontal and temporal white matter and prominent microglial dystrophy in frontal white matter. *C9orf72* carriers show a similar pattern but with less dystrophy. *MAPT* carriers have a high burden of microglia in temporal white matter but more microglial activation in temporal grey matter.
- Regional differences in microglial function between mutations may contribute to differences in neuronal vulnerability, atrophy, and network dysfunction across the spectrum of familial FTLD. The marked microglial dystrophy observed in frontal white matter in *GRN* carriers may represent premature microglial senescence in this region. This may contribute to the early frontal white matter vulnerability and white matter hyperintensities observed in neuroimaging studies of FTLD-*GRN*. Future studies should examine a panel of microglial markers across the broad spectrum of FTLD, to expand knowledge of regional microglial dysfunction in FTLD.