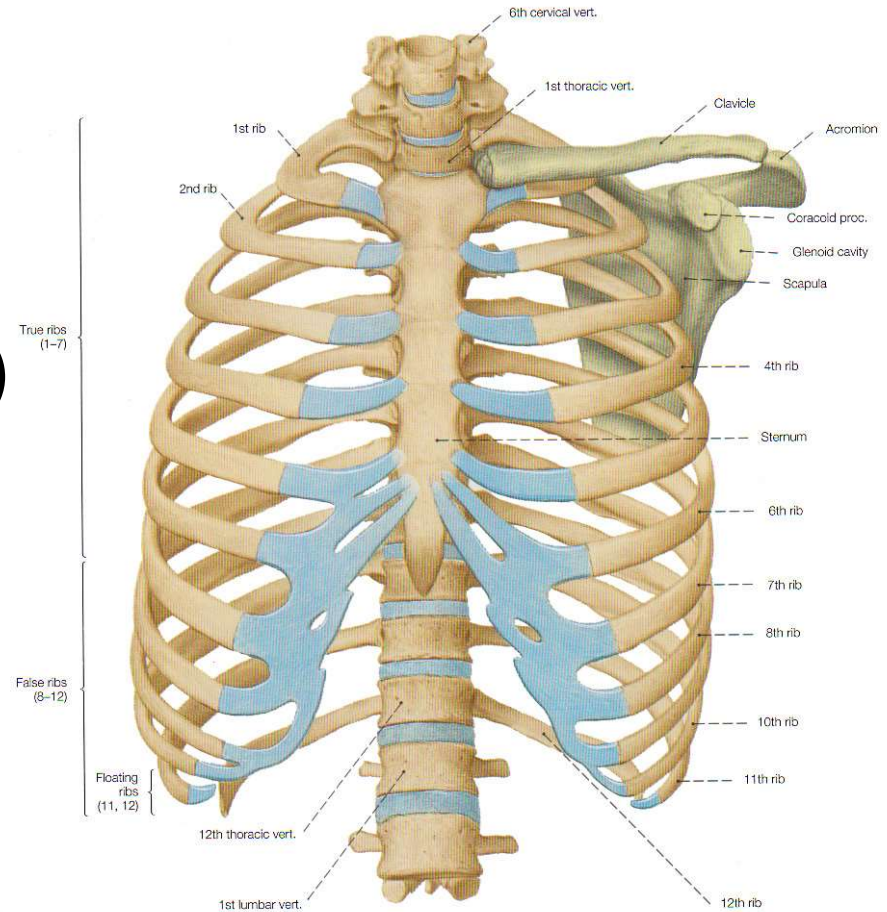
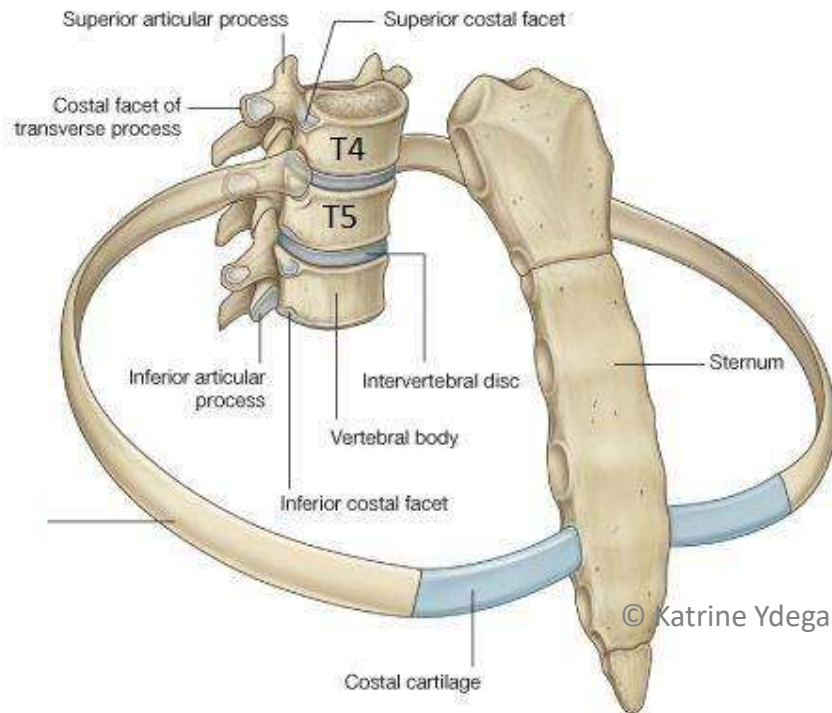


[brystkassen]

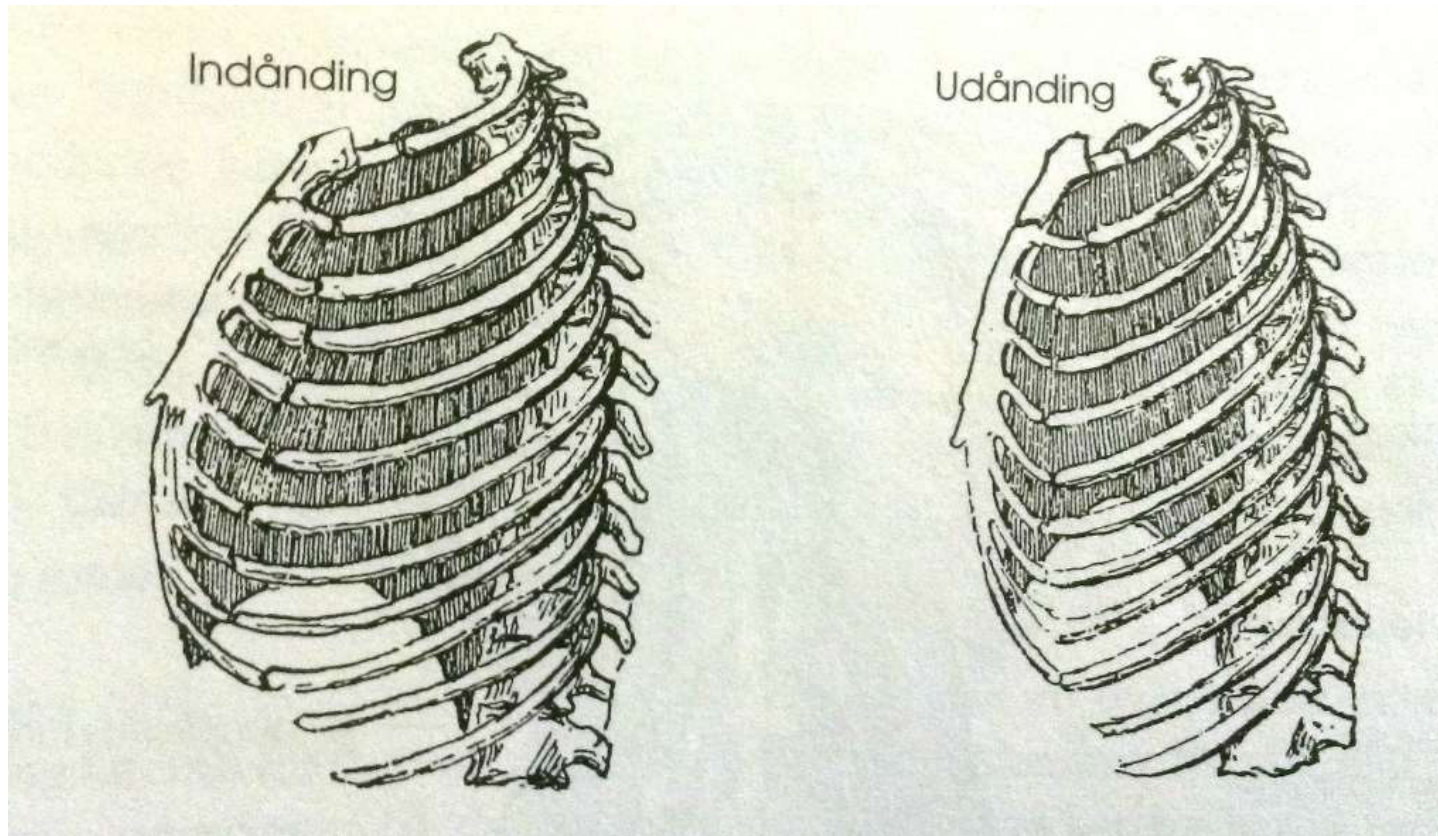
Ægte ribben (1-7)

Falske ribben (8-10)

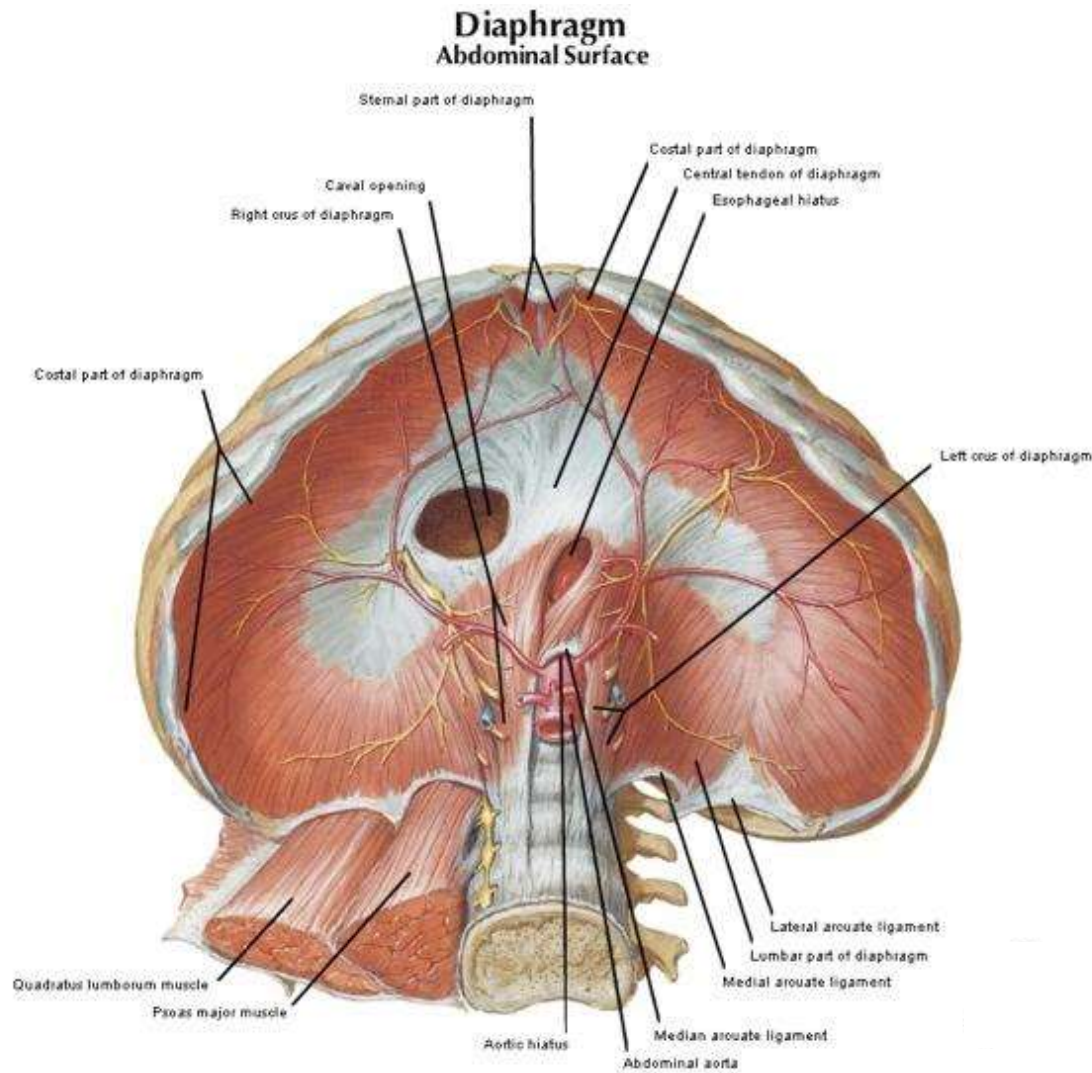
Flydende ribben (11-12)



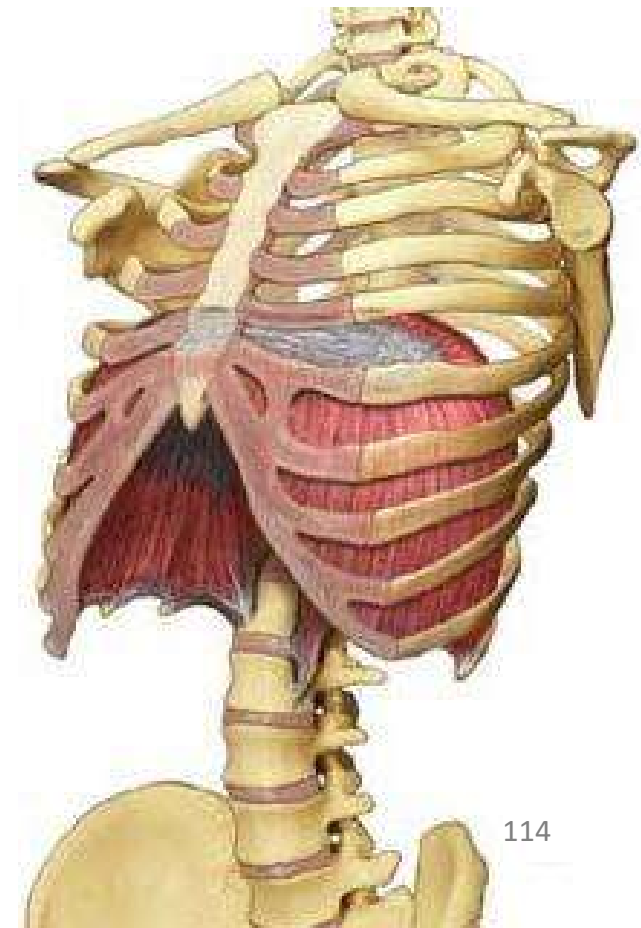
[respiration]



[musculus diaphragma]



© Katrine Ydegaard · Solrose · 2018



[musculi intercostales]

