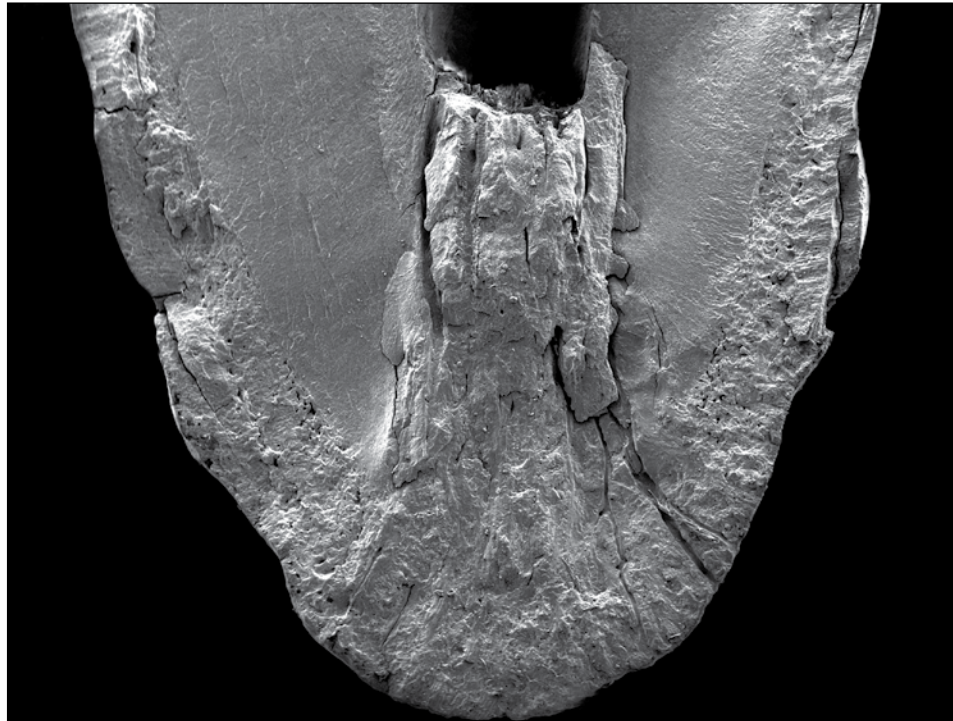


JOURNAL OF

VeterinaryDentistry



Official Journal of the

American Veterinary Dental Society
Academy of Veterinary Dentistry
American Veterinary Dental College
Academy of Veterinary Dental Technicians
Australian Veterinary Dental Society
Brazilian Veterinary Dental Association
British Veterinary Dental Association
Canadian Veterinary Dental Society
European Veterinary Dental College
European Veterinary Dental Society
Japanese Small Animal Dental Society

Volume 31 • Number 3 • Fall 2014

Anti-Plaque Gel as a Dentrifice

Mandibular Lip Avulsion Repair

SEM Evaluation of Tooth Root Apices

Hypercementosis in Geriatric Horses

Diseases Causing an Open Mouth in Cats

Apically Repositioned Flap for Gingival Enlargement



Generalized Hypercementosis in Geriatric Horses

Jens Arnbjerg, DVM

Summary:

*Hypercementosis has been described in the horse associated with painful tooth root resorption and infection in and around the roots of incisor teeth, or as painful swellings in the oral cavity in elderly horses. A screening radiological examination of 16 clinically normal horses older than 15-years showed varying amounts of hypercementosis, especially around the reserve crown and apices of the incisor teeth in 9 cases. The amount of cementum formation varied from several mm to 2-cm especially associated with the roots of the maxillary and mandibular third incisor teeth. The periodontal ligament of the incisor teeth was always seen radiographically as a homogeneous and distinct radiolucent line surrounding the roots. Computed tomographic evaluation indicated that the hypercementosis was more pronounced on the labial aspect. The distinction between the enamel and cementum was more clearly delineated on computed tomographic imaging. Teeth in horses with acute angles between the maxillary and mandibular incisor teeth had greater hypercementosis than incisor teeth with more vertical angulation supporting the theory that stress on incisor teeth may be an etiological factor. Hypercementosis was also noted in the interradiolar area of worn cheek teeth but not exceeding the original outer shape of the roots. Histological examination of hypercementosis affected teeth showed no evidence of tumor or infection regardless of the location of the tooth. As in humans, hypercementosis does not require specific treatment unless secondary complications occur. **J Vet Dent 31(3); 153-159, 2014***

Introduction

Modern horse management has changed considerably in recent years, horses being more commonly owned as companion animals. Furthermore, geriatric equine management is more common for horse practitioners. These factors and the owners' concerns about equine dental management make dentistry and dental problems more dominant in equine general practice.

The cementum is a white or cream colored calcified connective tissue with a histological appearance similar to bone. In the infundibulum of the cheek and incisor teeth, cementum is produced to fill-up the infolding cavity before the teeth erupt.¹ The cementum is produced throughout life both around the roots and on the reserve crowns under the gingival surface. It is seen as a calcified mass attached directly to the reserve crown and root. Cementum is less resistant to wear compared to enamel, and thus appears smooth and yellow on the occlusal surface of aged, worn cheek teeth.² Cementum contains 65 % inorganic material and 35 % organic components and water.³ The radiological density is approximately 1200 - 1500 Hounsfield "units" (H). Dentin is

70 % inorganic material and 30 % organic components and water with a density of 1600 - 1800 H. Enamel is 96 - 98 % inorganic material, with a density of 2400 - 2600 H due to its lower water content. Therefore, based on these similar densities, it may be difficult to distinguish the relatively small amount of cementum from dentin using standard radiography.

The purpose of this study was to examine a group of horses > 15-years of age, with no history of masticatory or dental problems as assessed by their owners, in order to give an impression of non-clinical dental problems in elderly horses. Specifically, this study was undertaken to focus on hypercementosis, which is often seen on radiographs affecting the incisor teeth in elderly horses.

Materials and Methods

Sixteen horses were examined clinically and were considered normal based on eating habits and body condition. Horses were between 15 and 36-years-old (mean = 23.7-years). All dental examinations (macroscopic and periodontal probe measurements) were performed after the owner's consent. Each patient was documented by taking digital color pictures and dental radiographs. Horses euthanized in this study were euthanized for reasons other than dental disease. Computed tomographic (CT) imaging was done in 4 of the 5 euthanized horses. In all euthanized horses, the head was sectioned and the maxillary and mandibular arcades were examined macroscopically. Live horses (11/16) were sedated with a combination of acepromazine (0.01 mg/kg), butorphanol (0.01 mg/kg), and detomidine (0.01 mg/kg) intravenously, and radiographed using an open-mouth, intraoral technique for imaging the incisor teeth.⁴ The cheek teeth were imaged using a traditional oblique radiographic technique.¹ Three of the horses had follow-up oral examinations including radiographs at 8 to 10-months after the initial examination, with 1 of these horses examined again 30-months after the initial examination. The angles between the maxillary and mandibular incisor teeth were estimated visually as high or low.

Tooth specimens were obtained by boiling the heads and bleaching the teeth with hydrogen peroxide. Specimens were prepared for histological examination after decalcification and cutting from specimens fixed in 4 % formaldehyde. The sections were stained with hematoxylin and eosin (H&E).

Results

Clinically, the gingival surface and the clinical crown of the incisor teeth appeared normal in 11/14 horses. There were variations in the angle between the maxillary and mandibular incisor teeth, as well as crown height, albeit at times unexpectedly so based on the horse's age (Fig. 1). In some cases, very old horses had normal upright incisor teeth and no hypercementosis. In two cases, the abaxial contour of the mandible had gingival protrusion around the roots of the maxillary (103, 203) and mandibular (303, 403) third incisor

teeth. Three horses had 1 or 2 uncomplicated transverse crown fractures or worn incisor teeth (Fig. 2).

Radiographs showed a smooth incisor tooth root surface in all horses. Hypercementosis was seen in 9/16 horses (mean age = 26.1-years) examined as a deposit of a mostly

homogeneous highly dense material extending from the tooth root to the crown, with variations in size (Table 1, Figs. 2 and 3). Horses with no radiographic signs of hypercementosis (7/16) were younger (mean age = 20.5-years). Cementum deposits were often larger around the mandibular incisor

Figure 1

Lateral (A) and frontal (B) photographs of the incisor teeth in a 28-year-old gelding showing long clinical crowns with a low angle between the maxillary and mandibular arcades. No signs of gingival infection or swelling are present.

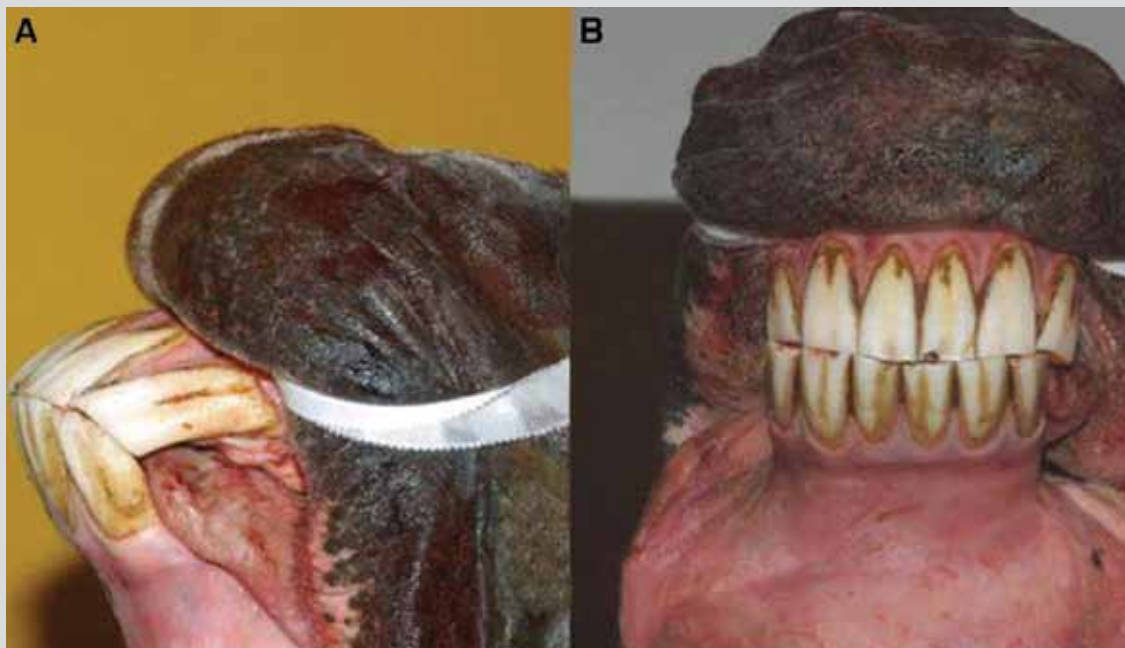


Figure 2

Radiographic images of the maxillary (A) and mandibular (B) incisor teeth in a 35-year-old mare showing varying degrees of hypercementosis. Note the enlarged contour especially around all of the third incisor teeth due to the thick layer of cementum and expanded alveolus. The periodontal ligament space is widened, but distinct. The right mandibular first (401) incisor tooth (black arrow) is fractured/worn.

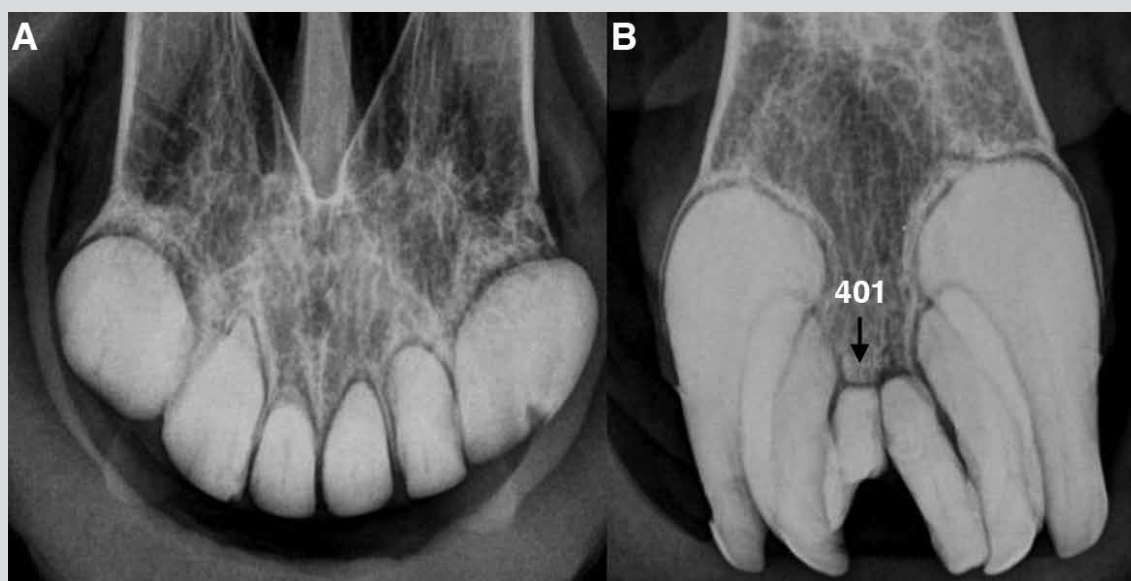


Table 1

Relationship between the development of hypercementosis and the angle between maxillary and mandibular incisor teeth in aged horses.

Horse	Sex, Age	Cementosis (Incisor Teeth)	Incisor Cementosis Resorption	Cementosis (Cheek Teeth)	Incisor Angle	Live/Euthanized
Ali	G 22	Slight	No	Yes	High	Live
Island	G 30	No	No	Yes	High	Live
Daisy	M 15	No	No	No	High	Live
Freya	M 15	No	No	No	High	Live
Islandic	G 28	No	No	Slight	High	Live
Kaj	G 16	Yes	Yes	No	Low	Live
Ninja	M 35	Yes	No	Slight	Irregular	Live
Anat	G 36	Yes	No	Yes	Low	Euthanized
Nana	G 19	No	No	No	High	Euthanized
Trine	M 22	Yes	Yes	No	Low	Live
Erna	M 23	Yes	No	No	Low	Live
Anna	G 25	Yes	No	No	Low	Live
Mitzie	M 15	No	No	No	High	Live
Anton	G 28	Yes	No	Yes	Low	Euthanized
Iceland	G 29	Yes	No	Yes	Low	Euthanized
Lester	G 22	No	No	Yes	High	Live

Figure 3

Radiograph of the maxillary incisor teeth (A) in the 28-year-old gelding of Figure 1. Note the enlarged reserve crowns and roots, especially of the right (103) and left (203) maxillary incisor teeth. The right (101) and left (201) first, and left (202) second maxillary incisor teeth are mildly affected however the left first (201) incisor and canine (104, 204) teeth are considered normal. The periodontal ligament space is seen clearly, but it is difficult to distinguish between the original roots due to excessive cemental deposition and hypercementosis. The enlarged reserve crowns appear uniform in structure with a distinct periodontal ligament space and linear radiolucent pulps. No resorption is observed. The mandibular incisor teeth (B) show varying degrees of hypercementosis especially around the reserve crown and roots of the left mandibular second (302) and third (303), and right mandibular third (403) incisor teeth. The right mandibular first (401) incisor tooth and the mandibular canine (304, 404) teeth have minimal cementosis. No resorption is observed.

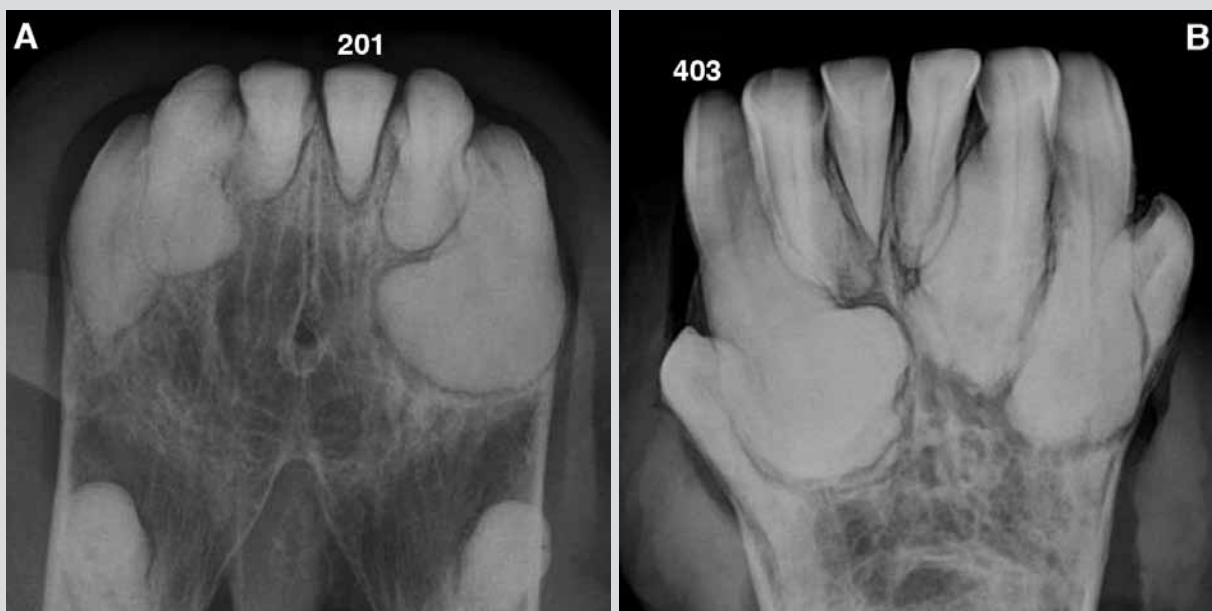

Figure 4

Post-mortem computed tomographic (CT) image at the transected left (203) maxillary and left (303) mandibular third incisor teeth in the 28-year-old gelding of Figure 1. The image shows the low density area of hypercementosis (white arrows) that is thicker on the lingual compared with the labial side.

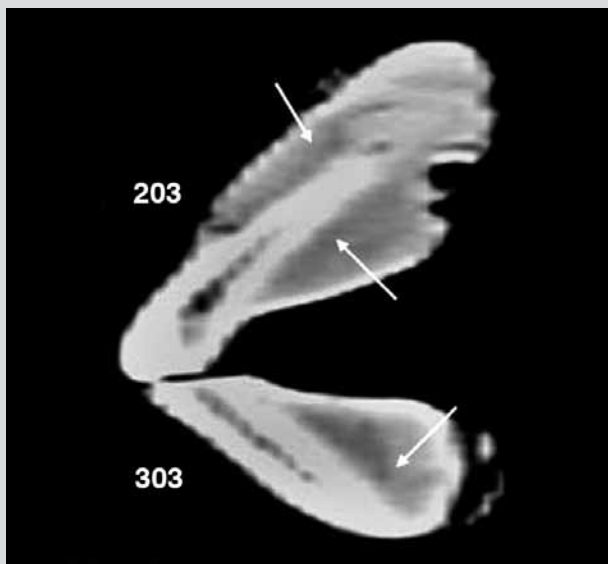


Figure 5

Post-mortem computed tomographic (CT) image at the transected right maxillary third (107) premolar tooth in the 28-year-old gelding of Figure 1. Note the dentin/enamel remnants of the reserve crowns (black arrows) and the darker grey hypercementosis between and distal to the roots (white arrows). The healed alveolus of the left maxillary second (207) premolar tooth shows a trabecular bone pattern present (circle).

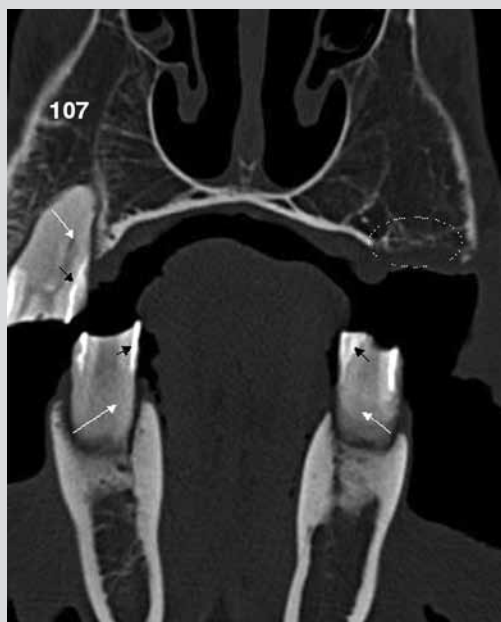

Figure 6

Post-mortem computed tomographic (CT) image at the transected maxillary and mandibular third molar tooth in the 28-year-old gelding of Figure 1. There is minimal hypercementosis affecting the right (111) and left (211) maxillary incisor teeth with no dentin/enamel remnants. The roots of the right (411) and left (311) mandibular third molar teeth were normal with hypercementosis between and below the reserve crowns. The cementum (black arrows) has vertical linear patterns and is darker than the dentin surrounding the remaining enamel.

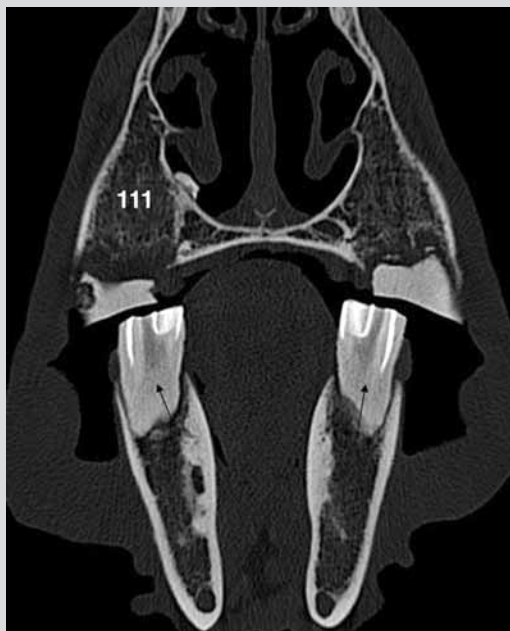

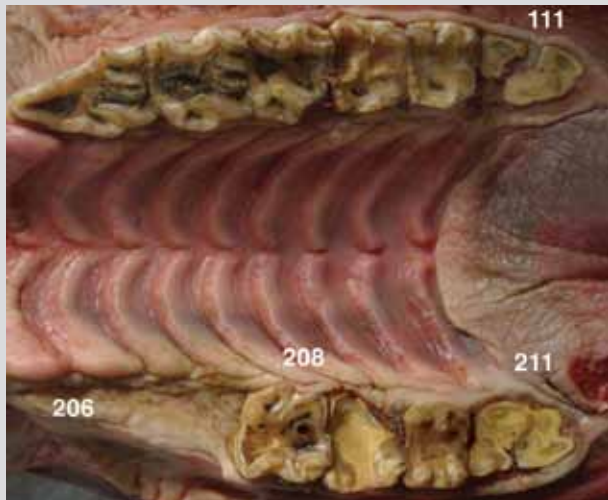
Figure 7

Post-extraction photograph of the longitudinally sectioned right mandibular third (403) incisor tooth in the 35-year-old mare of Figure 3 after extraction. Note the apparent vital pulp and the hypercementosis (white and irregular) particularly around the root, and to a lesser extent affecting the reserve crown.

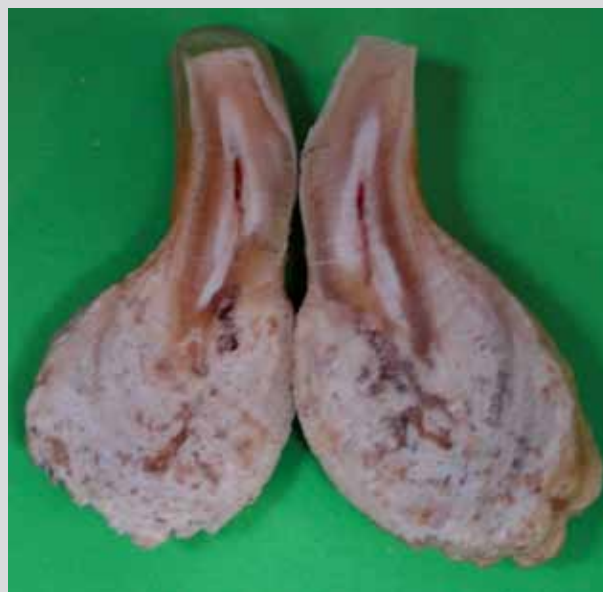

Figure 8

Post-mortem photograph of the maxillary cheek teeth in the 28-year-old gelding of Figure 1. These teeth have varying degrees of wear. Note the apparent healing at the locations of the missing left maxillary second (206) and third (207) premolar teeth.



teeth compared with the maxillary incisor teeth. Subjective assessment of the radiological density indicated that cementum deposits were slightly less dense than dentin. The cementum deposits varied in thickness between 2 and 20-mm and were most clearly seen on the CT images (Figs. 4-6). The change in cementum deposit contour was easily observed on both CT images and radiographs. The extent of cementum deposition varied from localization around the root apex, along the entire root, and advancing to the level of the clinical crown (Fig. 7). Generally, the thick cementum deposition appeared homogenous in 7 cases and was irregular in 2 cases. However, the reserve crowns and roots were seemingly not affected to the same extent as the enamel or dentin as noted by an absence of radiolucent lesions.

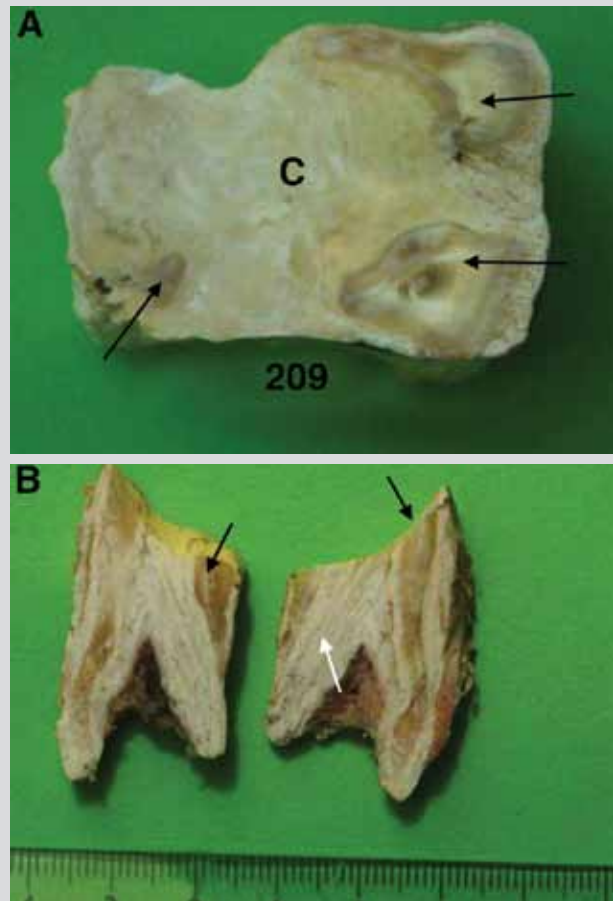
The alveolar bone between the incisor teeth was nearly absent, occasionally. However, the outer contour of the mandible and maxilla had mild enlargement in 2 cases noted by minor thickening especially around 103, 203, 303, and 403. Cementum deposition was usually more concentrated on the axial and lingual aspects of the roots compared with the abaxial and labial aspects (Fig. 7). Generally, the 103, 203, 303, and 403 were most commonly affected (Fig. 3). The periodontal ligament space of the incisor teeth was always homogeneous and distinct, but often widened in teeth with hypercementosis (Figs. 2 and 3).

CT examination showed greater distinction of enamel, dentin, and cementum compared with radiographs when imaging incisor and cheek teeth (Figs. 4-6). Similar to radiographic findings, the periodontal ligament space was distinct and uniform, but slightly widened.

Gross examination of an incisor tooth with severe hypercementosis following longitudinal sectioning showed that the tooth had been viable based on the appearance of the pulp (Fig. 7).

Figure 9

Photograph of the occlusal surface (A) of the left maxillary first (209) molar tooth in the 28-year-old gelding of Figure 1 showing the cementum (C) occupying the original space between the remnants of the roots and reserve crowns. The remnants of the roots (black arrows) are darker in color (dentin) and lighter (enamel) compared with the "marbled" cementum (C). The longitudinally sectioned 209 (B) shows the linear irregularities in the cementum (white arrow) between the root remnants (black arrows). The occlusal surface is opposite the measure (cm).



The cheek teeth varied in length, but not necessarily as expected based on the horse's age. The wear of individual teeth varied considerably between horses, but also within the individual horse, noted by wave formation of the dental arcade. In extreme cases, no remnants of the teeth could be seen and the gingiva covered the area where teeth had been located (Fig. 8). In cases with rapid wearing of the cheek teeth, the cementum was found to fill the space between the remaining roots as a slightly softer and yellowish material (Fig. 9). This response was limited to the area around the body of the cheek teeth.¹

Clinical hypercementosis lesions of cheek teeth were confirmed based on radiographic and CT examinations (Figs. 5 and 6). No signs of cemental destruction were noted. The alveoli in edentulous areas were filled with what appeared as regular trabecular bone (Fig. 5). The cementum was nearly uniform on radiographic and CT images, however longitudinal sectioning of cheek teeth revealed layers of cementum in an

Figure 10

Photomicrograph of the right mandibular third (403) incisor tooth in the 35-year-old mare of Figure 7 showing dentin (left), and border zones between dentin and original cementum (black arrows), and between original cementum and irregular hypercementosis (white arrows). No resorption of dentin or of the original cementum is present [H&E, original magnification = 80X].

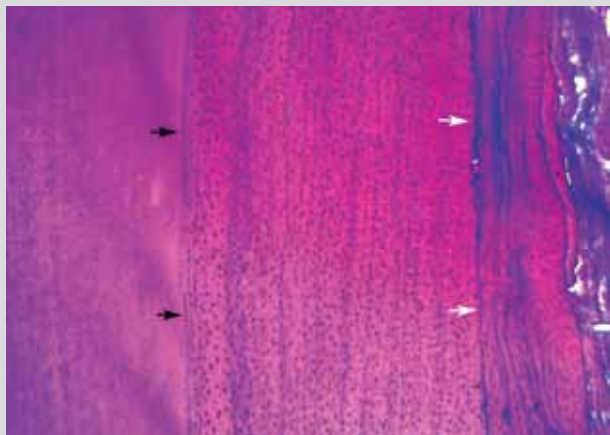
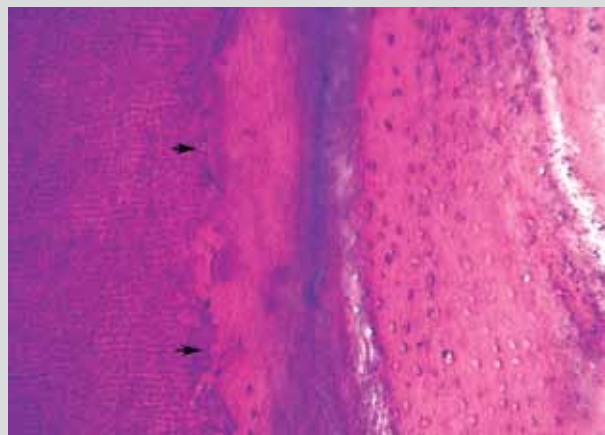


Figure 11

Photomicrograph of the right mandibular third (403) incisor tooth in the 35-year-old mare of Figure 7 showing dentin (left) with irregular resorption lacunae at the border zone between dentin and hypercementosis (arrows). Original cementum and resorbed parts of the dentin have been replaced by irregular hypercementosis [H&E, original magnification = 200X].



irregular pattern parallel to the vertical axis of the tooth between the remaining roots (Fig. 9). There was limited cementum deposition on the peripheral aspects of roots. It appeared that cementum had replaced the outer surface of cheek teeth roots and that alveolar bone had been replaced by trabecular bone (Figs. 5, 6, and 9).

Generally, horses with a more acute incisor angle had greater cementum deposition (Table 1, Fig. 4). In the 3 horses undergoing serial examination, there were no substantial changes in the amount of cementum deposition (Fig. 2).

Histological examination showed extensive masses of cementum-like tissue attached to root dentin (Figs. 10 and 11). Unfortunately, histology was somewhat dominated by artifacts, apparently as a result of handling before histological cutting with varying degrees of mineralization of the cementum leading to cracks and empty spaces. Numerous cell lacunae were seen in the cementum. However, they appeared empty possibly due to drying during the fixation and preparation process. The boundary line between dentin and cementum was straight and uniform in some areas, whereas in many areas the dentin was replaced by cementum in small and large resorption lacunae at the dentin surface. The periodontal ligament was not retained in the specimen, however there was no indication of ankylosis between cementum and alveolar bone. The general impression from the histological examination was irregular hypercementosis with no signs of neoplasia or infection. The histological findings were similar for incisor and cheek teeth.

Discussion

In humans, hypercementosis was originally described as “periodontium that (*sic*) will be seen to leave its normal path and extend itself to envelop its enlarged root”.⁵ Similar to the horses in this study, humans typically have no clinical

symptoms associated with even dramatic radiological signs of uncomplicated hypercementosis unless there is associated tooth resorption or periodontal disease.^{6,7,8} However, a different study described lesions similar to cementoma in 3 horses that showed signs of pain, discomfort during mastication, and increased tooth mobility.⁹ Further, the periodontal ligament space was radiologically distinct in the cases reported here with hypercementosis, while horses with lesions termed cementoma had obliteration of the periodontal ligament with an indistinct periodontal space.⁹ Therefore, it would appear that the lesions reported here are distinctly different than cementoma based on both radiographic and histological assessment.

In humans, there seems to be a relationship between occlusal pressure or stress and the formation of hypercementosis.¹⁰ This relational cause has also been proposed in the horse.¹ In this study, the majority of hypercementosis lesions were observed in those incisor areas with the most severe occlusal stress (Table 1, Fig. 4). Hypercementosis in cheek teeth was seen only around the roots of teeth with severe wear, likely related to focal occlusal stress (Figs. 5 and 6). The pathologic changes could be related to the pressure/traction on the periodontal ligament in incisor teeth and worn cheek teeth.

Therefore, this study supports the concept of occlusal pressure/stress as an etiological factor in the development of hypercementosis since such occlusal stresses are greatest in horses with an acute, low angle between the maxillary and mandibular incisor teeth where the angle is most acute, especially affecting 103, 203, 303, and 403. Similarly, exacerbated occlusal stress may be causative for hypercementosis between the roots of short, worn cheek teeth.

In earlier studies, most horses with hypercementosis also had tooth resorption and clinical signs of dental disease.^{6,7,11,12} It has been postulated that there is an association between tooth

resorption and hypercementosis in horses.^{6,7} Oral pain was reported as a clinical sign associated with tooth resorption.^{6,7} In the study reported here, dental examinations were done primarily as a screening for general oral health problems in elderly horses without clinical signs of dental disease. One incisor tooth had a suspicious resorptive lesion, however there were no clinical signs associated with periodontitis, gingival infection, or pain. Therefore, hypercementosis lesions are not necessarily associated with tooth resorption.

Based on the findings of this study and those published previously, there appears to be no treatment to prevent hypercementosis in the horse. In humans, it is considered unnecessary to explore treatment options unless there is evidence of periodontitis in combination with hypercementosis.^{5,2} Similarly, the clinical significance of hypercementosis in the geriatric horse appears of limited clinical importance unless secondary complications occur.

^a Siemens Somatom Emotion, Single Slice Spiral Scanner – Software A 45 A, Forchheim. Germany

Author Information

Copenhagen University, SUND, University Hospital for Small Animal, Department of Veterinary Imaging, Dyrlægevej 32, 1870 Frederiksberg C, Denmark. Email: jarn@image.dk

Acknowledgment

The author thanks Professor Jesper Reibel, Faculty of Odontology, Department for Oral Pathology and Medicine, Copenhagen University, for his skillful help with the histological preparation and interpretation.

References

1. Dixon PM. Disorders of development and eruption of teeth and developmental craniofacial abnormalities. In: Easley J, Dixon PM, Schumacher J, eds. *Equine dentistry*. 3rd ed. Philadelphia: Elsevier/Saunders, 2011; 99-113.
2. Baker GJ, Chandler KJ. Dentistry in the geriatric horse. In: Bertone J. *Equine geriatric medicine and surgery*. Edinburgh: Elsevier/Saunders, 2006; 51-58.
3. Dixon PM. Dental anatomy. In: Easley J, Dixon PM, Schumacher J, eds. *Equine dentistry*. 3rd ed. Edinburgh: Elsevier/Saunders, 2011; 51-76.
4. Arnbjerg J. Radiographing the incisor and canine teeth of horses. *J Vet Dent* 1996; 13:74.
5. Gardener BS, Goldstein H. The significance of hypercementosis. *Dental Cosmos* 1931; 73:1065-1069.
6. Staszky C, Bienert A, Kreutzer R, et al. Equine odontoclastic tooth resorption and hypercementosis. *Vet J*. 2008; 178:372-379.
7. Lee S. Equine odontoclastic tooth resorption and hypercementosis. *Austr Vet J* 2010; 88:N23-4.
8. Seed R, Nixon PP. Generalized hypercementosis: case report. *Primary Dent Care*. 2004; 11:4, 119-122.
9. Kreutzer R, Wohlsen P, Staszky C, et al. Dental benign cementomas in three horses. *Vet Pathol* 2007; 44:533-536.
10. Leider AS, Garbarino VE. Generalized hypercementosis. *Oral Surg Oral Med Oral Pathol* 1987; 63:375-380.
11. Baratt RM. Equine incisor resorptive lesions. In: *Proceedings of the 21st Annual Veterinary Dental Forum*, Minneapolis 2007; 23-30.
12. Caldwell LA. Clinical features of chronic disease of the anterior dentition in horses. In: *Proceedings of the 21st Annual Veterinary Dental Forum*, Minneapolis 2007; 117-121.

ERRATUM

The correct authorship for the Veterinary Dentistry at Work feature entitled *Odontoblastoma in a calf*. *J Vet Dent* 2013; 30: 248-250 should be: Lepri Elvio, DVM, PhD; Avallone Giancarlo, DVM, PhD; Mandara Maria Teresa, DVM; Vitellozzi Giovanni, DVM. The Editor apologizes for this oversight.